

**"CASE STUDY OF  
ECHINOCOCCOSIS/HYDATIDOSIS IN DIFFERENT  
HOSPITALS OF KATHMANDU"**



**A DISSERTATION SUBMITTED IN PARTIAL FULFILLMENT OF  
THE REQUIREMENTS FOR MASTER'S DEGREE OF SCIENCE  
IN ZOOLOGY (PARASITOLOGY)**

**BY:**

**KHIMANANDA BASHYAL**

**CENTRAL DEPARTMENT OF ZOOLOGY**

**INSTITUTE OF SCIENCE AND TECHNOLOGY**

**TRIBHUVAN UNIVERSITY**

**KIRTIPUR, KATHMANDU**

**NEPAL**

**“CASE STUDY OF  
ECHINOCOCCOSIS/HYDATIDOSIS IN DIFFERENT  
HOSPITALS OF KATHMANDU”**



**A DISSERTATION SUBMITTED IN PARTIAL FULFILLMENT OF  
THE REQUIREMENTS FOR MASTER'S DEGREE OF SCIENCE  
IN ZOOLOGY (PARASITOLOGY)**

Entry No: *67/183*  
Zool Dept: *Parasitology*  
Signature: .....  
Date: *26.07/22*

**BY:**

**KHIMANANDA BASHYAL  
CENTRAL DEPARTMENT OF ZOOLOGY  
INSTITUTE OF SCIENCE AND TECHNOLOGY  
TRIBHUVAN UNIVERSITY  
KIRTIPUR, KATHMANDU  
NEPAL**

# TRIBHUVAN UNIVERSITY

## CENTRAL DEPARTMENT OF ZOOLOGY

Kirtipur, Kathmandu  
NEPAL



### RECOMMENDATION

This is to certify that **Mr. Khimananda Bashyal** has successfully completed the dissertation work entitled “**Case Study of Echinococcosis/Hydatidosis in different Hospitals of Kathmandu**” as a partial fulfilment of the requirements for master’s Degree of science in Zoology with parasitology (as a special paper) under my supervision. His work is an original one and deserves to recommendation. To my knowledge this work has not been submitted for any other degree.

*Mahendra*

.....  
Mr. Mahendra Maharjan

Lecturer

Central Department of Zoology

T.U. Kirtipur, Kathmandu

Nepal

Date : 06/12/22

# TRIBHUVAN UNIVERSITY

CENTRAL DEPARTMENT OF ZOOLOGY

Kirtipur, Kathmandu  
NEPAL



Ref. No.:

Subject:-

Date: .....

## CERTIFICATE OF APPROVAL

On the recommendation of supervisor **Mr. Mahendra Maharjan**, this dissertation work of **Mr. Khimananda Bashyal** is approved for the examination and is submitted to the Tribhuvan University in partial fulfilment of the requirements for the Degree of Master's of Science in Zoology with Parasitology as a special paper.

.....  
Prof. Dr. Tej Kumar Shrestha  
Head of Department  
Central Department of Zoology  
T.U. Kirtipur, Kathmandu  
Nepal

Date : .....



# TRIBHUVAN UNIVERSITY

Phone No. : 3-31896

CENTRAL DEPARTMENT OF ZOOLOGY  
Kirtipur, Kathmandu  
NEPAL



Ref. No.:

Subject:-

Date: .....

## CERTIFICATE OF ACCEPTANCE

We, the members of expert committee, evaluated with oral examination the dissertation work entitled, "Case Study of Echinococcosis/Hydatidosis in Different Hospitals of Kathmandu" submitted by Mr. Khimananda Bashyal is accepted in partial fulfillment of the requirements for awarding Master's Degree in Zoology with Parasitology as a special paper.

### EXPERT COMMITTEE

Mr. Mahendra Maharjan  
Supervisor

Prof. Dr. Tej Kumar Shrestha  
Head of Department  
Central Department of Zoology

External Examiner

Dr. Gambhira Lal  
Raj Bhan Chary  
M.B.S., M.S., F.I.C.S.  
Consultant Cardio-  
Thoracic Surgeon  
Birnanda Hospital - III  
Churi, 1.

Date : .....

Date : .....

## ACKNOWLEDGEMENT

First and foremost, it gives me pleasure to express my enormous gratitude and respectable appreciation to my supervisor **Mr. Mahendra Maharjan**, lecturer Central Department of Zoology, T.U. for well guidance, continuous support, suggestions and encouragement that inspired me to carry this giant task with motivation, conviction and proper vision.

I am thankful to Prof. **Dr. Tej Kumar Shrestha**, Head, Central Department of Zoology, T.U. for his kind co-operation, valuable suggestion and for providing me an opportunity to carry out this work.

I express my deep sense of gratitude to my teachers: Prof. Dr. Purna Nath Mishra, Dr. Narayan Prasad Pokheral, Dr. Ranjana Gupta for giving due attention during the period of this study and again I am thankful for their kind co-operation.

I am thankful to Dr. G.L. Rajbhandary, cardiovascular thoracic surgeon, Birendra Military Hospital, Dr. Prakash Saymi T.U.T.H. cardiovascular thoracic surgeon, Dr. Anil Pahari Physician T.U.T.H., Dr. Mahesh Khakurel General Surgeon T.U.T.H., Maharajgunj.

I am thankful to Dr. Monohar Lal Shrestha, Dr. V.K. Sharma, Dr. M.K. Malla General Surgeon Bir Hospital. I am thankful to Dr. A.K. Banskota, Dr. J.L. B., Dr. Sujay Shad for valuable suggestions.

I am equally thankful to all the friend of my class, the teachers and staffs of Central Department of zoology who helped me directly or indirectly during this period.

I would like to extend the sincere thanks to my mother for strong support and inspiration in my whole academic carrier.

There are many more to whom I owe my thanks. To all of them, my sincerest thanks wishes for their well being.

*Krishyal*

Khimananda Bashyal

T.U., Reg. No. : 12125-90

Batch No. : 1998-2000

Roll No. 413

*knb809@gmail.com*

## ABSTRACT

A total 13 cases of Echinococcosis / Hydatidosis were observed in Tribhuvan University Teaching Hospital and Bir Hospital Kathmandu during June 1999 to July 2000. Out of 13 cases, 8 were male (61.5%) and 5 were female (38.46%) with age ranges from 4 years to 64 years. Infected dogs are the potential risk of transmitting hydatid disease in human beings. Large number of hydatidosis patients were found to be under 10 years of age group i.e. 4 (30.7%) followed by 3 (23.07%) in productive age group i.e. 21-30 and 31-40. All of the children below age of 10 years had pet dogs in their home and allow them to roam outside. In T.U.T.H., Maharajgunj among 7345 major operated cases 7 (0.09%) were due to hydatidosis and in Bir Hospital among total 6435 major operated cases 5 (0.07%) were due to hydatidosis. Among 13 hydatidosis operated cases in T.U.T.H., Maharajgunj, as well as Bir Hospital, 8 (61.8%) cases were performed thoracotomy and 5 (38.46%) were performed laparotomy. District wise hydatidosis operated patient showed maximum 8 (58.4%) were from outside the valley while 5 (41.6%) were the residence of Kathmandu. None of the patiente of hydatid disease had knowledge about the disease. The term itself is unfamiliar for them and none of them found to be feeding only cooked meat to their pet dog. Only 2 person (15.3%) were vegetarian and 11 person (84.6%) was non-vegetarian. The disease is not directly related with food habit of the people but related to the hygiene, sanitation and environmental contamination with infective stage of Echinococcus eggs discharged by infected dogs.

# CONTENTS

	<i>Page No.</i>
Recommendation	I
Certificate of approval	II
Certificate of acceptance	III
Acknowledgement	IV
Abstract	VI

## CHAPTER-I

<b>Introduction</b> .....	<b>1</b>
1.1 Hydatidosis (Hydatid Disease) .....	1
1.2 General Account: Life cycle of <i>Echinococcus granulosus</i> : .....	3
1.3 Pathogenesis and Pathology .....	5
1.4 Clinical Manifestations .....	6
1.5 Types of hydatid Cysts.....	7
1.6 Diagnosis.....	9
1.6.1 Laboratory diagnosis .....	9
1.7 Immunodiagnosis .....	10
1.8 Imaging Technique .....	10

## CHAPTER-II

<b>Objectives</b> .....	<b>11</b>
-------------------------	-----------

## CHAPTER-III

<b>Literature Review</b> .....	<b>12</b>
--------------------------------	-----------

## CHAPTER-IV

<b>Methodology</b> .....	<b>21</b>
4.1 Diagnosis Procedure .....	21
4.2 General Procedure.....	21
4.3 Laboratory Collection .....	22
4.4 Post Operative Follow Up.....	22
4.5 Data Analysis .....	22

## CHAPTER-V

<b>Result.....</b>	<b>23</b>
5.1 Survey Result .....	23
5.2 Knowledge About Hydatidosis Among Hydatid Patient .....	24
5.3 Observational Finding in O.T. ....	26
5.4 Facilities for Hydatidosis Operation in Hospitals.....	30

## CHAPTER-VI

<b>Discussion.....</b>	<b>36</b>
------------------------	-----------

## CHAPTER-VII

<b>Conclusion and Recommendation .....</b>	<b>42</b>
7.1 Conclusion .....	42
7.2 Recommendations .....	43
<b>References .....</b>	<b>44</b>
Annex-I .....	55
Annex-II .....	57
Annex-III.....	58
Annex-iv.....	59
Annex-V.....	60

## LIST OF TABLES

*Page No.*

Table 1 : Age wise hydatidosis cases in relation to dog and other factors: .....	23
Table 2 : Age and gender distribution of hydatiosis patients.....	25
Table 3 : Hydatidosis operated cases in Kathmandu during June 1999 to July 2000.....	28
Table 4 : Types of Hydatidosis Operation in Hospitals .....	29
Table 5 : District wise categorization of patients operated in Kathmandu .....	30
Table 6 : Facilities available in T.U.T.H. & Bir Hospital for hydatidosis operation .....	31

## LIST OF FIGURES

	<i>Page No.</i>
Figure 1: <i>Echinococcus granulosus</i> .....	2
Figure 2: Life cycle of <i>Echinococcus granulosus</i> .....	4

## LIST OF PHOTOGRAPHS

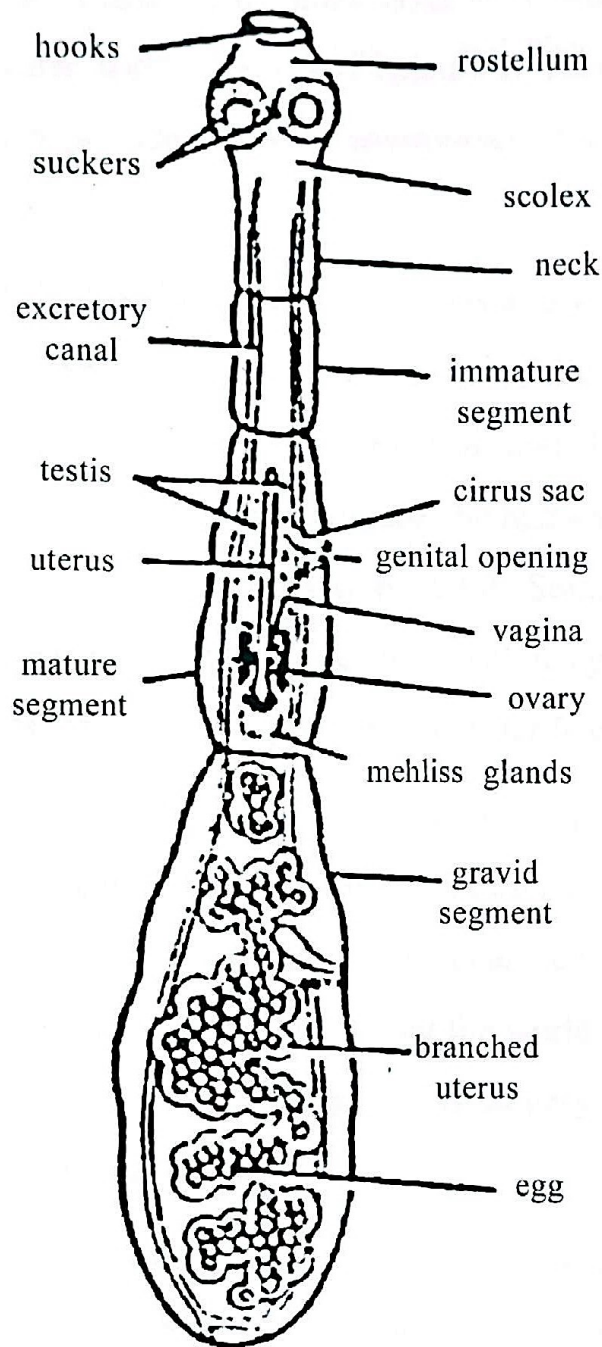
List of Photographs.....	32-34
Figure 3 C.T., Scan report of hydatidosis patient.....	35

# CHAPTER-I

## INTRODUCTION

### 1.1 Hydatidosis (Hydatid Disease)

Hydatid disease is a parasitic zoonotic disease caused by larval form of *Echinococcus granulosus*, *Echinococcus multilocularis*, *Echinococcus oligarthrus* and *Echinococcus vogeli* in a global sense. Man including other herbivorous animals like, sheep, pig, buffalo, camels are usually suffered by this disease, when the infective stage of eggs of *Echinococcus granulosus* are swallowed by man is an accidental host. In human beings usually it causes unilocular hydatid cyst in liver and lungs and occasionally other parts of the body. Human cystic Echinococcosis is world wide in distribution, mainly in sheep and cattle raising regions. The disease is prevalent in most of the Asian Countries.; India, Pakistan, Afghanistan, Nepal, Bhutan, Sri-Lanka and Bangladesh. *Echinococcus granulosus* is a small tapeworm measuring 3-8 mm. in length which consists of a scolex (head), neck and strobila of 3-4 segments. The first segment is immature, second segment is mature while the third (and often 4<sup>th</sup> when present) is gravid. The scolex shows four suckers within two rows of hooks. The terminal gravid segment which contains several hundreds of eggs devoid of uterine openings. The segment therefore, always bursts before or after passage in the stool; to release hundreds of eggs. These eggs are brown, spherical and has two layers an outer thin wall and inner embryophore. Each eggs contains a hexacanth embryo with three pairs of hooklets. These eggs excreted in the faeces of the dog are infective to man, sheep, cattle and other intermediate hosts.



**Figure 1: *Echinococcus granulosus* (from small intestine of dog): By Dr. Sood Ramnik**

Typically unilocular hydatid cyst is found in human beings. The cyst become mature within one year, after its localization in liver or lungs. It becomes a fluid-filled bag-shaped structure usually measuring up to 5cm. in diameter. The cyst wall composed of 2 layer: an outer laminated layer (ectocyst) and an inner germinal layer (endocyst). The

outer layer is non nucleated and the inner layer is nucleated which gives rise to brood capsules with a clear and colourless fluid known as the hydatid fluid, which provides suitable environment for growing brood capsules and scolices.

The hydatid fluid is slightly acidic and has a low specific gravity; A large number of brood capsules and free Protoscolices resembling sand grains float in the fluid forming so called hydatid sand. The hydatid fluid is highly toxic and antigenic, if rupture within the human body, produces anaphylactic reaction which may even be fatal. Sometimes if brood capsules fail to develop or even if develop within cyst, they do not contain any scolices. This type of cysts are called sterile or acephalo cyst.

Hydatidosis in man is caused by infection with larval forms of *Echinococcus granulosus* or *Echinococcus multilocularis* and usually present with symptoms from hepatic or pulmonary cysts (Rajbhandary 1998). It is a wide spread problem throughout the world including Nepal until recently the only effective treatment was surgery. (Schantz 1996, Joshi et. al, 1996, Rajbhandary 1998).

In Nepal the infection of the hydatidosis is increasing day by day. Adequate research has not been carried out yet. Most of the people are ignorant about this disease. An epidemiological study carried out emphasizing the municipality area showed 40% human hydatid cases in Kathmandu (Joshi, et. al 1996).

## **1.2 General Account: Life cycle of *Echinococcus granulosus*:**

*Echinococcus granulosus* is a small worm belongs to the class cestoda, the life cycle of the parasite complete within 2 hosts:

Definitive hosts: canines Wolf, Jackal and Fox (dog being the ideal host). The sexually mature worms resides in the small intestine of the dog and discharges numerous eggs in their faeces. Man and other herbivorous animals (sheep, cattle, pig, goat, horse etc.) are the Intermediate hosts and when eggs of cestode parasite are swallowed (Mostly Children) who usually handle the dogs or play with dogs are at high risk of getting infection including contaminated vegetables, food and drinking water.

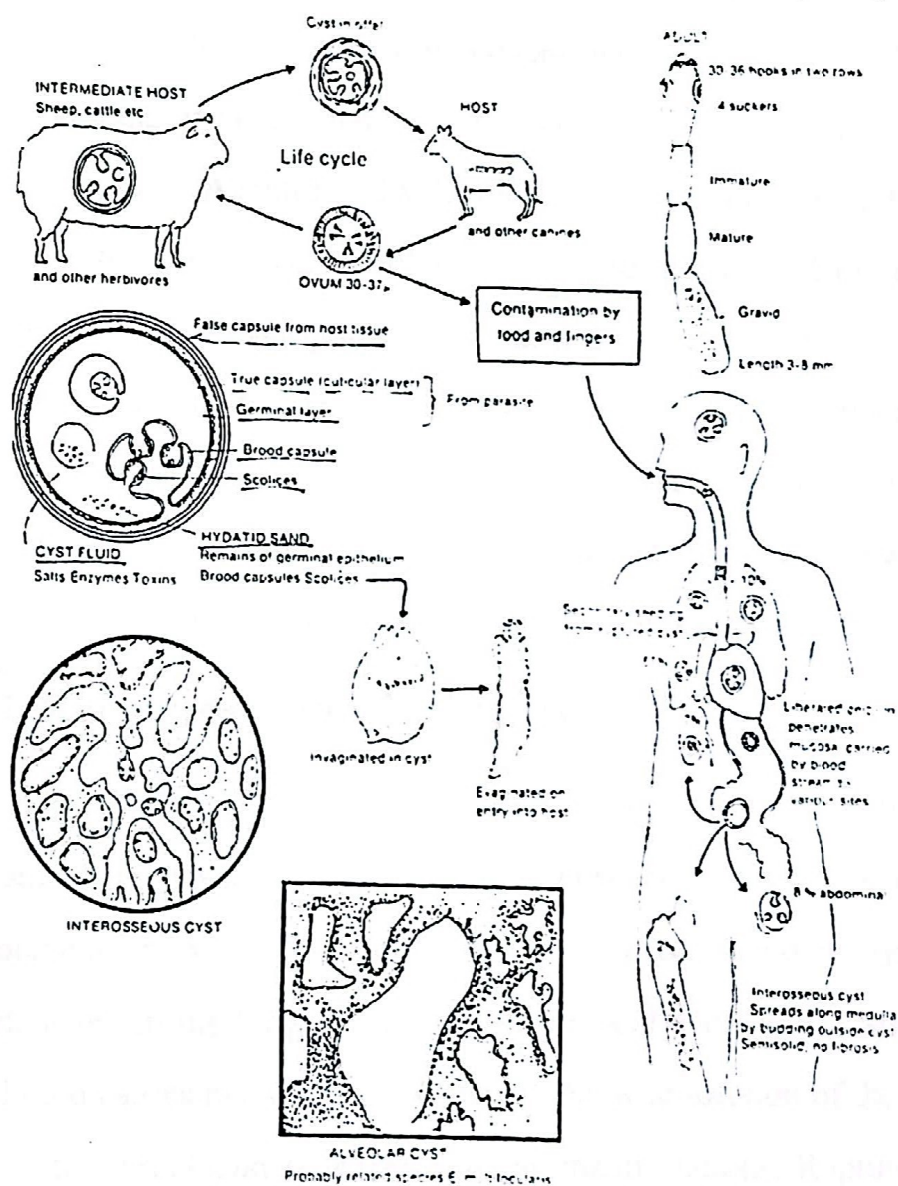


Figure 2: Life cycle of *Echinococcus granulosus* (Parasitology protozoology and helminthology by Dr. Sood Ramnik)

The embryos are hatched in the duodenum, within 8 hours after ingestion, the embryo pass through the intestinal wall to enter the portal veins radicles and are carried to the liver (This is the first filtering organ) Some of them may pass through the hepatic capillaries to enter the pulmonary circulation (second filtering organ). Few embryos may even pass through the pulmonary capillaries to reach systematic circulation to be lodged in various organs. Whenever the embryo settles, it forms a hydatid cyst, the young larva is transformed into a hollow bladder from the inner surface develop several brood capsules with scolices. A hydatid cyst developing from a single egg (onchosphere) may contain several thousand scolices. A mature fully developed scolex is the end product and represents full biological development. These fertile hydatid cyst, if ingested by a dog, develop into adult worm in 6-7 weeks, in the intestine however, this hardly happens as the dog do not have access to the hydatid cysts present in human viscera, therefore the cycle comes to a dead end. The natural cycle is hence carried on by dog and sheep. Life span of an adult worm is about 6 months, that of larval stage is many years.

### **1.3 Pathogenesis and Pathology**

The development of the cysts in various organs of the body causes mechanical trauma and produces various pressure effects, depending on the location of cysts. The cyst in the liver causes jaundice and portal hypertension, in the lung produces dyspnoea and haemoptysis and in the spinal cord causes neurological symptoms. Slow absorption of the hydatid fluid in the circulation sensitizes allergic manifestations. Rupture of the hydatid cyst causes anaphylactic shock and oedema by rapid absorption of hydatid fluid in the circulation causing development of secondary hydatid

cysts in the body. The hydatid cyst in the liver, lung and other organ causes foreign body type reaction in the surrounding tissues.

#### **1.4 Clinical Manifestations**

The parasite causes mainly hepatic and pulmonary hydatid disease in man. The condition remains asymptomatic throughout the life in a majority of cases. It is detected when cyst ruptures and give rise to anaphylactic reactions. The clinical manifestations of hydatid disease depend on the size, location and number of hydatid cyst. e.g. mechanical pressure on the surrounding tissues even 5 to 20 years after infection by the hydatid cyst. Hydatid cyst are most commonly found in the liver and lung. In the lung, the cyst is always intra capsular, and produces the signs and symptoms of the intra-thoracic growth. The condition may manifested as dry cough, chest pain, or haemoptysis. The hydatid cyst of the liver or spleen may present as an abscess. Hydatidosis of the liver may present as abdominal pain or a palpable abdominal mass. Hydatid cyst of the bone cause rapid erosion of the bone leading to multiple fractures and degeneration of bone structures.

The cyst in the brain, heart, kidney or orbit often cause serious symptoms and often are fatal. Cysts in the brain may cause epilepsy and blindness. Occasionally due to high intracystic pressure, the cyst may rupture. A rupture hydatid cyst produces two risks.

- i. Free and unusually large volume of hydatid fluid, which when partially absorbed in the circulation, bronchi, peritoneum or pleura, produce a sudden anaphylactic shock which may be fatal.

- ii. This results in the formation of new secondary hydatid cyst in the various parts of the body due to dissemination of the scolices by the circulation.

## **1.5 Types of hydatid Cysts**

### **i. Lung Cysts**

These may be developed from the primitive lung buds near the trachea or main bronchi. There are no communications with the bronchi even though they are lined with respiratory epithelium and have a tendency to become infected. Removal is advised for this reason. Lung cysts may contain air or fluid and may be single or multiple. The most common cause of multiple lung cyst is pulmonary hydatid disease, although this is unusual except in endemic areas.

### **ii. Liver cysts**

Liver abscess are often large by the time of presentation with upper abdominal discomfort or may present often minor abdominal trauma as an acute abdomen due to rupture of the cyst into the peritoneal cavity. Diagnosis is suggested by the finding of a multilocular cyst on the ultrasound and is further supported by the finding of a floating membrane within the cyst on C.T. Scan. A active cyst contain a large number of smaller daughter cyst. If rupture in biliary tract producing obstructive jaundice or into stomach, clinical and radiological diagnosis can be supported by serology for antibodies to hydatid antigen in the form of an Enzyme – Linked Immunosorbent Assay (ELISA). In the first instance a course of albendazole or mebendazole may be tried failure to respond to medical treatment usually requires surgical intervention, although percutaneous treatments with hypertonic saline and alcohol have been

attempted. Evacuation of the cyst contents. If contaminated peritoneal cavity during surgery by hydatid daughters, drug therapy with albendazole and adding paraziquantel perioperative. A biliary communication should be actively sought and sutured.

➤ **Unilocular Cysts (Liver cysts)**

- ✓ Spherical filled with clear cystic fluid, cyst wall three layered.
- ✓ Surrounding inflammatory reaction and fibrosis after years may die or shrink, calcify.
- ✓ General allergy, eosinophilia, asthma, etc.
- ✓ Pressure effects: Local tissue damage, obstruction of natural channels.
- ✓ Leakage or rupture – cause allergy, anaphylactic shock, sometimes secondary implantation (e.g. peritoneal) secondary infection with abscess formation.

➤ **Osseous cysts**

- ✓ Poorly develop cuticle
- ✓ No fibrous (sometimes cellular infiltration)
- ✓ Sometime leading to bone destruction
- ✓ Spontaneous fracture.

➤ **Alveolar cysts (Lung cysts)**

- ✓ Irregular shape, spongy in nature and devoid of cystic fluid commonly sterile and it undergoes degeneration and calcification.
- ✓ Local pressure effects
- ✓ Allergy
- ✓ Germinal epithelium acts as neoplasm with local infiltration or distant metastases.

Hydatid cyst in man grows just upto 5 cm. in diameter at the end of first year and the brood capsules and scolices begin to appear. The clinical manifestations of hydatid disease mimic a wide variety of illness. The signs and symptoms are dependent upon the location of the cyst. When spherical it produces a visible swelling; the clinical manifestation of slowly growing tumour like growth with eosinophilia may be suggestive of the disease.

## **1.6 Diagnosis**

### **1.6.1 Laboratory diagnosis**

- a. Casoni's reaction (introduced by casoni in 1911) intra-dermal injection of 0.2 ml. of a fresh sterile hydatid fluid (by using a seitz filter) produces a large wheel (5cm in diameter) within half an hour in all positive cases. It shows multiple pseudopodia and fades in an hour or so for control, sterile normal saline (0.2 ml.) is similarly injected (by using a separate needle and syringe) on the other arm. Hydatid fluid from human cases.
  - ✓ Peripheral blood smear shows moderate eosinophilia.
  - ✓ Serological tests: Precipitin reaction and CFT done in the hydatid antigen are also found to be positive. Other test available are haemagglutination test flocculation and ELISA test. Indirect fluorescent antibody test is very useful and immuno electrophoresis technique is also very well accepted.
  - ✓ Exploratory cyst puncture by fine needle aspiration reveals scolices or hooklets in fluid. This is however, a dangerous procedure (to be avoided).

## **1.7 Immunodiagnosis**

Diagnosis of hydatid disease by enzyme-linked immunosorbent assay (ELISA) serum test, due to the organ or tissue localization of larval cestode cysts and the invariable lack of direct parasitological evidence of infection (no eggs are produced) immunological diagnosis of hydatid disease is performed by ELISA serum test.

## **1.8 Imaging Technique**

Useful for cyst in lungs and liver. X-ray ultrasound, C.T. Scan or M.R.I. Scanning may reveal the cyst. X-ray of a bone cyst shows a mottled bony appearance.

X-ray is frequently helpful shows hollow like cysts a small rim of calcification. The hydatid cyst shows with irregular margin or circumferences. X-ray is frequently helpful in the diagnosis of hydatid cysts of the lung, liver and extra-hepatic abdominal cysts. The ultrasound scintigraphy and recent radio-imaging procedures of value in the diagnosis of the hydatid disease. They show non-reactive (cold) cystic lesions in various organ and tissues.

## **CHAPTER-II**

### **OBJECTIVES**

1. To record the hydatidosis operated cases in T.U.T.H. and Bir Hospital of Kathmandu.
2. To analyze age and sex-wise infection of hydatidosis among the operated patients.
3. To evaluate diagnostic facilities available in hospitals for hydatidosis confirmation.
4. To find out awareness of the disease among the hydatid patients.

## CHAPTER-III

### LITERATURE REVIEW

*Echinococcus granulosus* is also known as the hydatid tape-worm or dog tape-worm. Hydatid cyst is the larval stage of the parasite. It produces unilocular Echinococcosis or hydatid disease in man and other herbivorous animals. Adult *Echinococcus* was described by Hartmann (1695) in the intestine of the dog. The larval form (hydatid cyst) subsequently was described by Goeze 1782.

Zeller (1854) observed the protoscolices of *Echinococcus* spp. while studying a presumed malignant tumour, "alveolar colloid" of the human liver. The second tropical species, *Echinococcus vogeli* also involves rodents as intermediate host, but the strobilar stage occurs in canids.

Four species of *Echinococcus* are now recognized. *Echinococcus granulosus*, *Echinococcus oligarthrus*, *Echinococcus multilocularis*, and *Echinococcus vogeli*.

In 1950, beginning investigations on St. Lawrence Island, Bering Sea, led to recognition of a cestode whose cycle involved rodents as intermediate hosts and whose larval stage (metacestode) produced typical lesions of alveolar hydatid disease in the human liver.

In Tunisia, The sex ratio of infected children and youth (0-19 years of age) is approximately 1:1 however, among adults it is 1:2 (male female), (Bchir et. al., 1987).

Although humans have limited or no direct contact with stray dogs, these dogs drink from open water sources, and have free access to

vegetable gardens, which are often unfenced and are believed to contribute to human exposure through these indirect means of eggs dispersion (Shambesh; 1992).

The National hydatid disease center of China (1992) reported surgically confirmed cases of cystic hydatid disease in Xinjiang 35% were in children under 15 years of age. Distribution of cases was similar among both sexes 49% were males and 51% were females.

Diagnosis of *Echinococcus* and dog taeniasis by the use of coproantigen ELISA technique has been described by Allan et. al. (1992).

Surgery may be impossible because of the patients' general condition and the extent and location of the cysts, under such conditions treatment with benzimidazole drugs may be tried. Approximately one third of patients treated with benzimidazole drugs have been cured of the cyst (e.g. complete and permanent disappearance of cysts) and an even higher proportion have responded with significant regression of cyst size and alleviation of symptoms (Davis 1989, Horton 1989, Moris 1992, Todorov 1992, WHO 1992).

Hao W. & Craig, P.S., (1994). Immunoglobulin G (IgG) subclass-specific antibody responses were investigated in both human cystic echinococcosis (CE) & alveolar echinococcosis (AE) by Enzyme Linked Immunosorbent Assay (ELISA) & western blotting sera were tested from 50 CE & 50 AE surgically confirmed cases using partially purified hydatid cyst fluid antigens B (Egb) & crude hydatid cyst fluid (Egcf) from *Echinococcus granulosus* & a protoscolex extract (Emp) prepared from *Echinococcus multilocularis* metacestodes. Eighty-nine percent of CE patients & 94% of AE patients were seropositive for total IgG

antibodies. The dominant IgG antibody isotype in both CE & AE was IgG<sub>u</sub> for which 73% of CE & 84% of AE case were seropositive in the ELISA. Antibodies were detected in 58% of CE & 84% of AE patients sensitivity for IgG<sub>2</sub> & IgG<sub>3</sub> was significantly lower for both CE & AE patients. The IgG<sub>4</sub> antibodies in CE patients predominantly recognized the *Echinococcus granulosus* antigen B subunits i.e. at 20, 16 & 12 KD, While IgG<sub>1</sub> antibodies primarily bound to the 38 KD subunit of antigen 5 from *E. granulosus* hydatid fluid. The possible functional significance of an IgG<sub>4</sub> response & the potential use of combined assessment of total IgG, IgG<sub>1</sub>, & IgG<sub>4</sub> antibodies in serologic diagnosis & follow up for human echinococcosis are discussed.

Golaszewski, and Susani, M., (1995). Reported a large hydatid cyst of the liver in pregnancy report on a primigravida, who was admitted in the 14<sup>th</sup> week of pregnancy because of recurrent vomiting & upper abdominal pain. The diagnosis of a large 20 cm. echinococcal cyst of the liver was confirmed by ultrasound an Indirect Hemagglutination Test (IHA). In the 19<sup>th</sup> week of pregnancy a subtotal cystectomy was performed under perioperative treatment with the anthelmintic drug Albendazole. The patient delivered a 1420 g. 41cm. premature boy in breech position at 33 week.

Surgery remains the treatment of choice for all forms of echinococcosis in humans however chemotherapy (e.g. albendazole, mebendazole, praziquantal and benzimidazole) plays an important role as a complementary treatment in complicated cases. Proper diagnosis of cases helps in proper treatment 55% male and 45% female had the

highest number of positive 68% (Joshi et. al., 1995). ELISA and the immunoblotting test are being used most commonly.

Young, T. H., et. al., (1996). Described hydatid cyst in the liver a 67 year old Taiwanese woman with multilocular hydatid cysts of the liver presented with a 5 month history of intermittent right upper abdominal discomfort, Abdominal ultrasonography & computed tomography showed multiple cysts in both lobes of the liver.

Mendez Montero, J.V., J. Arrazola Garcia, et. al., (1996). Fat fluid level in hepatic hydatid cyst: A new sign of rupture into the biliary tree? Objectives in this article, describe 3 hepatic hydatid cysts with fat fluid levels.

Kahalil, A., Salim B. et. al., (1996). Described Acute Cholecystitis and Cholangitis caused by *Echinococcus granulosus*, a hepatic hydatid cyst into the gall bladder with subsequent obstruction of the cystic duct by a daughter cyst acting as a ball - valve and causing acute calculous cholecystitis.

In most of the Europe *Echinococcus granulosus* is perpetuate in synanthropic (domestic) cycles with the dogs as final host and domestic ungulates (cattle, sheep, goat, pig, house donkey) as intermediate host (Scantz 1996).

Eckert, J. and Thompson, R.C.A., (1997). Described intraspecific variation of *Echinococcus granulosus* and related species with emphasis on their infectivity to humans. Four species are presently recognized within the genus *Echinococcus* namely *Echinococcus granulosus*, *Echinococcus multilocularis*, *Echinococcus Oligarthrus* and *Echinococcus Vogeli* which are infective to humans.

Primo. A., (1997), Described, Public health, importance of cystic echinococcosis in Latin America. Human cystic echinococcosis caused by larval *Echinococcus granulosus* is a zoonosis of major public health importance throughout Latin America.

Karim, D.F. et. al., (1997). Public health aspects of cystic echinococcosis in the Arab counties. Human cystic echinococcosis (CE) caused by larval *Echinococcus granulosus* is a zoonosis of major public health importance throughout the region comprising Arab countries are determined by epidemiological factors related to the size of stray dog population, its worm burden to the infection rates in the intermediate host reservoir livestock population. Socio-economic development & socio-cultural practices are considered important determinants in the continued transmission of the disease.

Karim, D.F. and Alkarmi, T., (1997). Immunopathology of alveolar echinococcosis. The pathogenesis of alveolar echinococcosis caused by the metacestode of *Echinococcus granulosus* is a process involving the host parasite interface with both local & distant systemic effects. The survival strategy of the parasite is to continuously subvert the host defenses just as the host responds to contain the infection. There is a complex of signal molecules mediating between parasite elaborated factors & specific & non-specific cellular immune responses behind the gross pathological picture of a space - occupying lesion. This paper attempts to summarize the relationship of experimental findings with the clinicopathological picture by outlining path ways that may be involved in the process of pathogenesis.

Eckert, J., Thompson, R. C. A., (1997). Categorized Intraspecific variation of *Echinococcus granulosus* & related species with emphasis on their infectivity to humans. 4 species are presently recognized within the genus *Echinococcus* namely *Echinococcus granulosus*, *Echinococcus multilocularis*, *Echinococcus oligarthrus*, *Echinococcus vogeli* which are infective to humans. Evidence for strain, diversity within the species. *Echinococcus granulosus*, previously mainly based on morphological, biological & biochemical features, has been principally confirmed by recent genetic studies.

Hao & Wen Guarg; (1997). Described public health importance of cystic echinococcosis in China cystic echinococcosis has been reported in 21 out of china's 31 provinces, autonomous regions & municipalities (approximately 87% of territory). It constitutes one of the major public health problems especially in several northwestern provinces & autonomous regions. Special attention is given to the Xinjiang, an endemic area about one sixth of the country's area with a human population of approximately 16 million.

Bengisun, U., et. al., (1997). Described surgical treatment of advanced alveolar hydatid disease of the liver: A report of five cases we report herein the cased of 5 patients with alveolar hydatid disease (AHD) of the liver who were diagnosed & underwent surgery at the department of surgery of Ankara University between 1989 & 1994. In all 5 patients the final diagnosis was established by frozen section of the lesion during laparotomy. Lesions of AHD were found only in the liver. Hepatic reactions including right lobotomy & segnentectomy were performed in 3 patients while palliative procedures were carried out in the remaining 2

patients with unresectable disease. There was no operative mortality & only one late death occurred 3 years after the hepatic resection. In this paper we present the clinical operative findings of these five patients their outcomes followed by a review of the surgical treatment of AHD.

Bitkowska, E., Golab E. et. al., (1997). Applied western bolt method to the serological diagnosis of hydatidosis in Poland. 46 sera and 1 cerebrospinal fluid samples from 47 patients suspected of hydatidosis were examined by western blot method and the results were compared with those of the indirect haemagglutination, immunosorbent electrophoresis and an Enzyme Linked Immunosorbent Assay (ELISA). The examinations confirmed high sensitivity and specificity of the reactions with 8 KDA antigenic fraction in the western bolt. The above data supported the concept that serological diagnosis of hydatidosis should be carried out using a high sensitivity screening test, such as ELISA then the western bolt method to verify positive results.

Altintas, N., (1998). Described cystic and alveolar echinococcosis in Turkey. Human cystic echinococcosis occurs in the eastern Anatolian region of the country.

Ockenga, J., Gebel M. et. al., (1998). Described ultrasound imaging diagnosis & follow up of an atypical hydatid cyst. Abdominal ultrasonography is the procedure of choice to diagnose hydatid cysts caused by *Echinococcus granulosus*. Use of 3D - sonography improved the sonographic diagnosis. Which could be confirmed by a fine needle biopsy complicated by an anaphylactic reaction.

Schoretsanitis G., et. al., (1998). Described an extremely rare case of primary hydatid cyst of the adrenal gland. Adrenal hydatid cysts are

usually a manifestation of generalized echinococcosis only 1 primary cases have so far been reported in the literature. The presentation is insidious correct preoperative diagnosis is difficult clinical & investigative findings are non-specific & ambiguous surgery is the treatment of choice.

Sapkas, G. et. al. (1998). Described hydatid disease of bones & joints, 8 cases followed for 4-16 years. Hydatid disease is a rare parasitic disease that seldom involves the skeleton. Treatment is difficult because of problems with preoperative diagnosis: the invasive nature of the bony involvement & the variables anaphylatic reaction to the cyst fluid antigen.

Sharma, M. C. et. al., (1998). Described the rare case of a hydatid cyst found in the breast of a 26 year old women clinically, the mass was at first suspected of being a fibroadenoma, but Fine Needle Aspiration Cytology (FNAC) yielded clear fluid only. Histopathologic examination of the resected specimen confirmed that it was a hydatid cyst.

Angulo, J. C. et. al., (1998). Isolated total 42 cases of retroversical (25) and retroperitoneal (17) hydatid disease was complicated male predominance of 25:1 was noted and age ranged from 8 to 79 years (mean  $42.2 \pm 5.4$ ). The most frequent presentation was a palpable mass in 29% of the cases followed by flank pain in 24% frequently in 17% urinary retention in 14% of cases. An isolated retroversical, retroperitoneal or even retrocurual cyst can be the unique manifestation of hydatid disease.

Valladares D. et. al., (1998). Described hydatid liver cyst perforation into the digestive tract complications of liver hydatid disease include those related to the compression of adjacent viscus, to the

infection of the cyst's contents or to the perforation of the cyst. perforations into hollow abdominal organs are rare, & can occur secondary to the infection of the cyst or to a primary pathology of the perforation of a liver cyst into the duodenum, 1 due to the presence of a duodenal ulcer, & 1 secondary to a hydatid abscess. The surgical treatment of the lesions and their complications was, in both cases, successful.

Midori A., Adachi K. et. al., (1999). Described the first Japanese case of alveolar hydatid disease with cutaneous subcutaneous lesion in 58 year - old man who developed an indurated substances tumour on the right side of the abdomen, had partial hepatectomy of the right lobe for echinococcosis 13 years earlier.

Essaadi, M., (1999). Described three cases of hydatid cysts of the thyroid gland were managed surgically at the ENT department of the August 20 Hospital in Casablanca Morocco. The diagnostic & therapeutic challenges raised by hydatid disease of the thyroid gland are emphasized.

Sammak, B. et. al., (1999). Described radiological manifestations of liver & gastrointestinal parasitic infections. Todorov, T. & Boeva. V., (1999). Human Echinococcosis in Bulgaria:

Yalcinkay I. et. al., (1999). Described surgical treatment of hydatid cyst of the lung: Reviewing 30 cases of Hydatid cyst disease in Turkey, especially in the east Anatolian region, as well as in many other place in the world.

# **CHAPTER-IV**

## **METHODOLOGY**

The study was conducted during June 1999 to July 2000. The method follows: Hydatidosis cases operation in T.U.T.H. Maharajgunj and Bir Hospital. The method applied for study was questionnaire survey, case studies, evaluation of diagnosis methods and surgery capabilities of the hospitals, to analyze age and sex-wise infection, awareness about disease among patients. A set of questionnaire was prepared, pretested and piloted. The final set of questionnaire was administered among the identified suspected hydatid disease patients admitted for the surgery in these hospitals and some patients family person also. The questionnaire is given in Annex-I.

### **4.1 Diagnosis Procedure**

The patients visited at physicians or surgeons with symptoms like breathing difficulties, chest pain, upper abdominal discomfort, upper abdominal pain, with fever, pressure effect, vomiting, diarrhoea etc. the result of referred conformation diagnosis, various examinations and tests were collected and analyzed e.g. X-ray, U.S.G., C.T. Scan and M.R.I. including with other general, routine tests.

### **4.2 General Procedure**

The detailed information from the patients entrance into the operation theater to exist of the patients from operation theater was observed. The procedure followed by the Doctor during operation, problems (physical, technical as well as other) were keenly noticed.

During the study period, 13 cases of hydatidosis were observed, questionnaire administered, photograph were taken and symptoms were analyzed. Hydatidosis cases admitted and readmitted with the final diagnosis of echinococcosis confirmed surgically, covering a period of one year who underwent surgery for hydatidosis in all surgical departments.

### **4.3 Laboratory Collection**

the liver and lungs hydatid cyst during operation was observed and after removal of the cyst was thoroughly examined and were collected in the laboratory. The cyst was microscopically observed to know the type of the cyst. Out of 13 cyst, 6 cyst contents was microscopically observed.

### **4.4 Post Operative Follow Up**

The patient was send in I.C.U. or in ward depending upon the patient situation; each and every operated patients were monitered 2 or 3 times to know the condition of the post operation and prescribed chemotherapy to the patients; in ward patient was kept for 5 to 15 days or more depending upon the patient situation. The suture was removed after 2 weeks or after completely healing of the wound. (surgical side).

### **4.5 Data Analysis**

The collected information and data were analyzed.

# CHAPTER-V

## RESULT

### 5.1 Survey Result

The questionnaire survey was conducted among hydatidosis patients and their family persons in T.U.T.H. Maharajgunj, and Bir Hospital. Among 13 patients 8 were male (61.5%) and 5 were female (38.46%) with the age ranges from 4 years to 64 years.

**Table 1 : Age wise hydatidosis cases in relation to dog and other factors:**

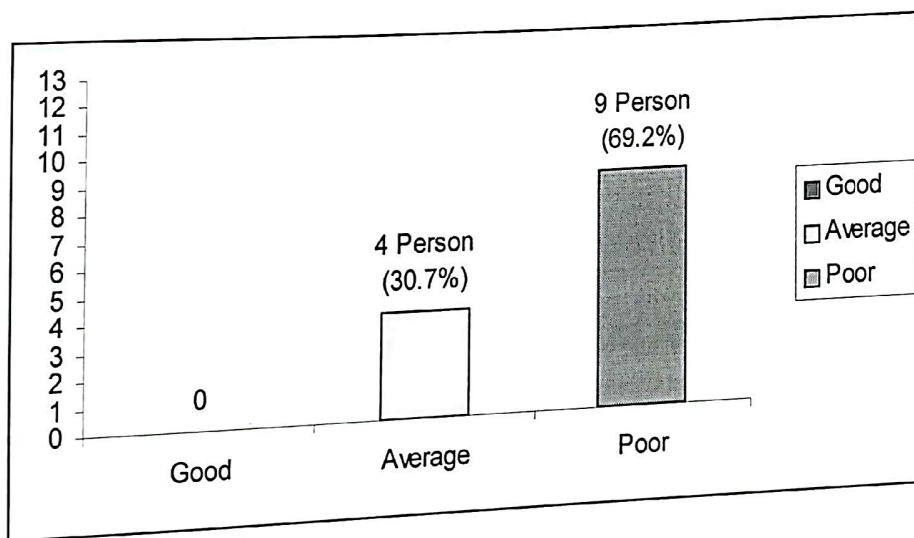
S.N.	Age/Year	No. of hydatid patient	%	No. of pet dog	Dog to roam outside	Children playing with dog	Stray dog problem	Vegetable wash in river water
1.	0-10	4	30.7	4	4	4		1
2.	11-20	1	7.6	1	1	1		1
3.	21-30	3	23.07	1	1	1	2	1
4.	31-40	3	23.07	-	-	-	3	2
5.	41-50	1	7.6	-	-	-	1	-
6.	51-60	-	-	-	-	-	-	-
7.	61-70	1	7.6	-	-	-	1	-
Total	4 years to 64 years	13		6(46.1%)	6(46.1%)	6(46.1%)	7(53.8%)	5(38.46%)

Infected dogs are the potential risk of transmitting hydatid disease in human beings. In order to know the probable risk of hydatidosis in all patients Interview was taken and data was analyzed. The result revealed that maximum number of hydatid patient were found to be under 10 years of age group i.e., 4 (30.7%) followed by 3 (23.07%) in age group 21-30 and 31-40. Among the children below 10 years, all the children have their

own pet dogs and they allow their pet dogs to roam outside the household and they prefer to play with their dogs. Another risk factor was the use of raw vegetable, and practice of washing them in natural water sources.

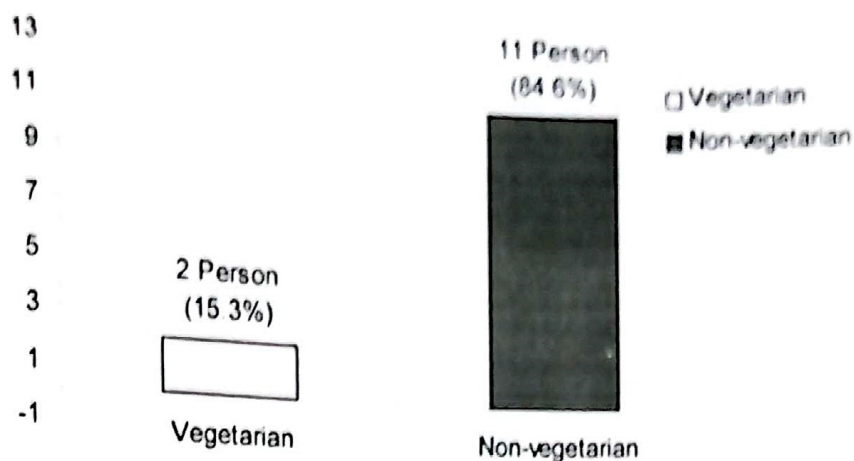
## 5.2 Knowledge About Hydatidosis Among Hydatid Patient

Among 13 hydatid disease patients, none of them had knowledge about hydatid disease. The term itself is unfamiliar for them. Most of them were only informed about accumulation of water in their liver or lungs and some of them had heard about the term hydatid cyst only from physicians prescription. All the patient with pet dogs feed all types of meat including cooked and uncooked. None of them found to be feeding only cooked.



**Graph 1: Knowledge about zoonotic disease (hydatidosis)**

This bar diagram showed that among 13 patients 4 (30.7%) patients had average knowledge about zoonotic disease and 9 (69.2%) patients had poor knowledge. They don't know any diseases that can be transmitted by dogs to human beings.



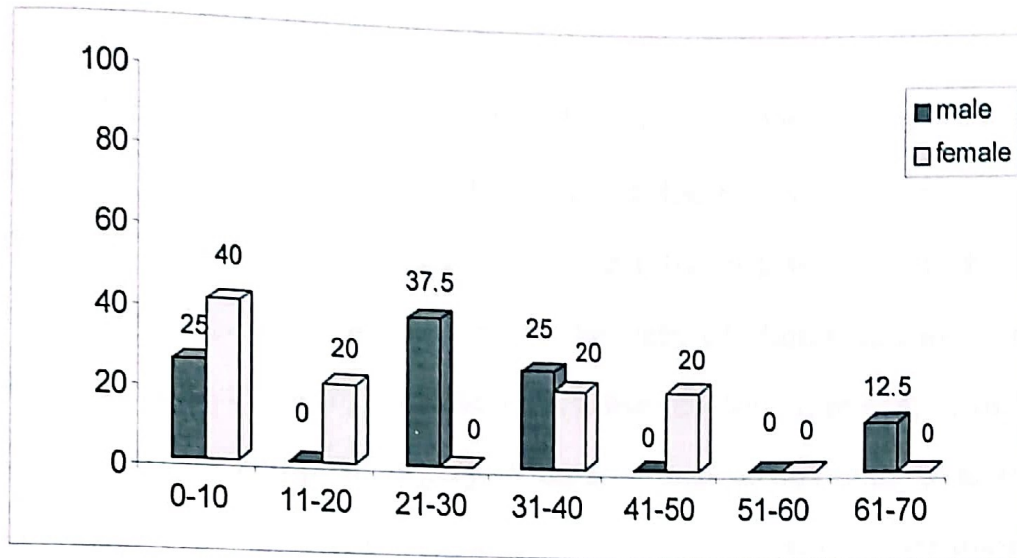
**Graph : 2 Food habit of patients**

This bar diagram showed that only 2 person (15.3%) was vegetarian and 11 person (84.6%) was non-vegetarian. By questionnaire it was found that above mentioned patients those who playing with dogs don't care about thoroughly hand wash and most of the patients was non-vegetarian usually consume Goat, Buffalo, Sheep, Pig etc. and few those who are vegetarian directly or indirectly associated with dog and few of them had cattle pet, bring them for grazing in open grazing ground which was not dog proof, that means knowledge about hydatidosis among infected patients was very poor.

**Table 2 : Age and gender distribution of hydatidosis patients**

S.N.	Age/Year	Male case no.	%	Female case no.	%	Total	Case
1.	0-10	2	25	2	40	4	30.7
2.	11-20	-	-	1	20	1	7.6
3.	21-30	3	37.5	-	-	3	23.0
4.	31-40	2	25	1	20	3	23.0
5.	41-50	-	-	1	20	1	7.6
6.	51-60	-	-	-	-	-	-
7.	61-70	-	-	-	-	1	7.6
	61-70	1	12.5	-	-	1	7.6
	Total	8	100	5	100	13	100

Age and sex-wise analysis of data revealed that out of 13 hydatidosis cases maximum 4 (30.7%) cases belongs to age group of 0-10 years. Among them 2 each were male and female. The infection rate was followed by 3 (23%) each in age group 21-30 and 31-40 years age group. Least no. of cases had been observed in rest of the age group.



**Graph : 3 age and sex-wise prevalence of hydatidosis in different hospitals of Kathmandu.**

### **5.3 Observational Finding in O.T.**

During the study period 13 cases of hydatidosis were observed among them 7 cases from T.U.T.H., Maharajgunj, 5 cases from Bir Hospital and one case from B. & B Hospital. In T.U.T.H., 6 cases referred to cardio-vascular thoracic surgical unit and one case with liver and Rt. lung hydatidosis, referred to general surgical unit and Cardio-vascular Thoracic Surgical unit, in Bir Hospital. All 5 cases referred to General Surgical unit and in B & B Hospital one case referred to Cardio-vascular Thoracic Surgical unit for this case Rt. lobectomy was done by T.U.T.H. Cardio-vascular Thoracic Surgeon. In T.U.T.H. patient age ranges from 4 years to 40 years among them 5 were male and two were

female. In Bir Hospital patient age ranges from 21 years to 64 years, among them 2 were male and 3 were female and in B & B Hospital one male 24 years patient with lung hydatid disease.

Above mentioned all 13 patients were surgically confirmed cases. All the case was operated under General Anaesthesia during operation monitor was kept (for check B.P., spo<sub>2</sub>, pulse, E.C.G. etc.) Low pressure cuff Endotracheal tube was intubated for liver hydatid disease case and double lumen E.T. tube was intubated with the help of laryngoscope, for most of the lung hydatidosis cases, and by anaesthesia machine O<sub>2</sub>, Halothane, O<sub>2</sub>, N<sub>2</sub>O, was given by the help of Bain's circuit or other anesthetic circuit, foley's catheter was inserted for urine output monitor during surgery and post surgery. After scrubbed scrub nurse, wear sterile gloves and gown, then kept all the surgical instruments, suture materials and other necessary things was kept in the dressing table, mayotable then surgeons scrubbed, wear sterile gown, gloves and came for surgery, first of all cleaned the patient surgical side by betadine solution, then sterile towel, peri sheet, table sheet, lap sheet was used according to need, incision was done by surgical knife, then guaze piece, tetras, and cotry was used for bleeding control, for lung hydatidosis case right or left thoracotomy was done.

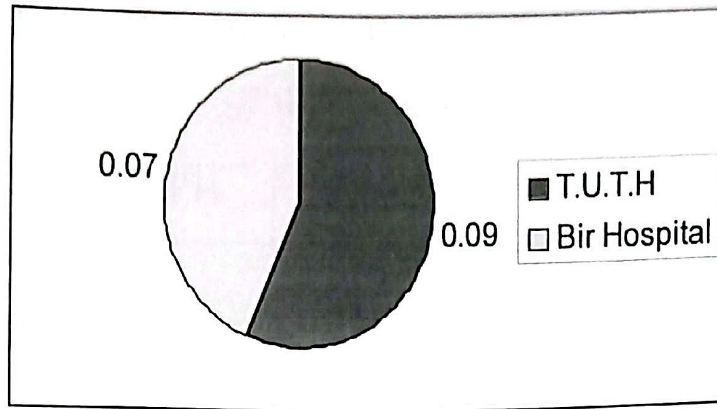
Transverse abdominal incision, or roof top, loperotomy was done for five hydatidosis case then costal margin retractor and other instrument used according to their need. During removal of cyst in most of the case prick the cyst, then make hole and suction was used to evacuate of the cyst fluid, then cyst was removed slowly, in few case cyst was rupture for that rapid suction was used to evacuate of the cyst content, then cyst was

removed slowly. The place where cyst located was washed by betadine solution and normal saline, the removed cyst was kept in the bowl and kept in sampling plastic bottle and send for H.P.E. (Histopathological Examination) in laboratory, then the surgical side was gradually closed layer by layer with suture material (e.g. prolene, vicryl, cronic silk, Nylon etc.) for each and every case drain was kept, in the surgical side. After complete the surgery, patients awake slowly then extubate the patient and when become fully conscious then send in ward or I.C.U. depending upon the patient situation, in ward patient was monitered 2 to 3 times to know the status of the patient and prescribed chemotherapy to the patient. Most of them had smooth post operative recovery and there was no post operative mortality.

All of them had course of antibiotics, and albendazole treatment for adult 400 mg twice daily orally for 4 weeks before and after surgery.

**Table 3 : Hydatidosis operated cases in Kathmandu during June 1999 to July 2000**

Hospitals	Major Operated cases	Hydatidosis cases	%
T.U.T.H	7345	7	0.09
Bir Hospital	6435	5	0.07
Total	13780	12	0.16



**Graph 4 : Hydatidosis case out of major operated cases**

This diagram shows that in T.U.T.H. Maharajgunj major operated cases 7345, among them hydatidosis case 7 and case percentage 0.09 percent and in Bir Hospital total major operated cases 6435 among them 5 was hydatidosis, percentage was 0.07 percent.

**Table 4 : Types of Hydatidosis Operation in Hospitals**

Operation types	T.U.T.H, Maharajgunj				Bir Hospital				Total Male	Total Female
	Male	%	Female	%	Male	%	Female	%	Male	Female
Thoracotomy	5	71.4	2	28.57	2	40	3	60	5	2
Laparotomy	-	-	-	-					2	5
Both	1	14.2	-						7	5
Total										

In T.U.T.H. all of hydatidosis patient had thoracotomy operation among them 5 were male (71.4%); two were female (28.57%) and 1 case (14.2%) and both thoracotomy and laparotomy. Bir Hospital all 5 hydatidosis patient had laparotomy operation, among them 3 (60%) were female and 2 (40%) were male, hence total 7 male and 5 female and one male patient from B & B Hospital had been operated during the study period.

**Table 5 : District wise categorization of patients operated in Kathmandu**

District	T.U.T.H.	Bir Hospital	Total	%
Kathmandu	4	1	5	41.6
Nawalparashi	1	2	3	25
Sarlahi	1	-	1	8.3
Lamjung	1	1	2	16.6
Kaski	-	1	1	8.3
Total	7	5	12	100

It is obvious that all the hydatid disease patients operated in Kathmandu were not residence of Kathmandu but maximum 5 (41.6%) patients operated in T.U.T.H. and Bir Hospital were the residence of Kathmandu. Which is followed by Nawalparasi 3 (25%), Lamjung 2 (16.6%) and 1 (8.3%) each from Sarlahi and Kaski. One case which hasn't been shown in table was from Pashupatinagar. The result indicated that the disease is scattered throughout the country.

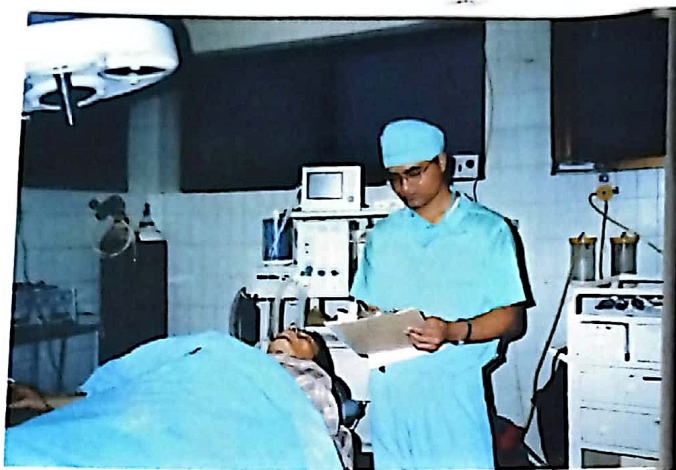
#### **5.4 Facilities for Hydatidosis Operation in Hospitals**

The facilities available hospitals are, T.U.T.H. Maharajgunj, Bir Hospital, Shree Birendra Military Hospital, Chhauni, B & B Hospital, Patan Hospital, Kanti Children Hospital etc.

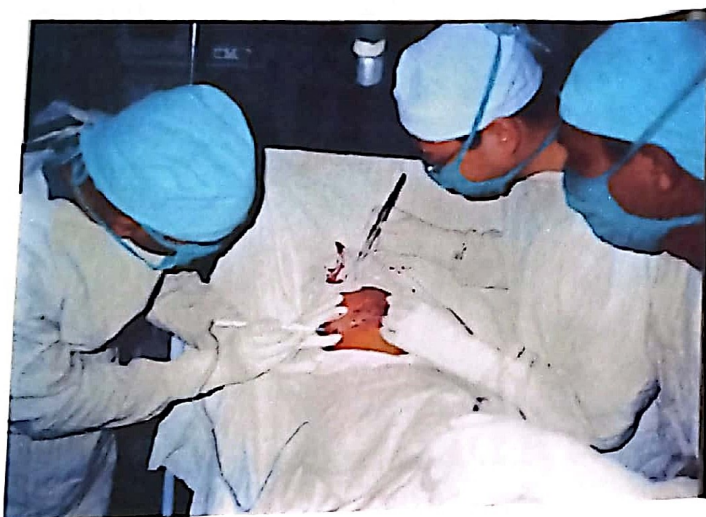**Table 6 : Facilities available in T.U.T.H. & Bir Hospital for  
hydatidosis operation**

Name	T.U.T.H	Bir Hospital
Man Power	Number of Physicians: 14 Number of surgeons: 12	Number of Physicians: 11 Number of Surgeons: 10
Diagnostic measures	X-ray, USG, C.T. Scan, M.R.I.	X-ray, USG, C.T. Scan,
Serodiagnosis (ELISA)	-	-

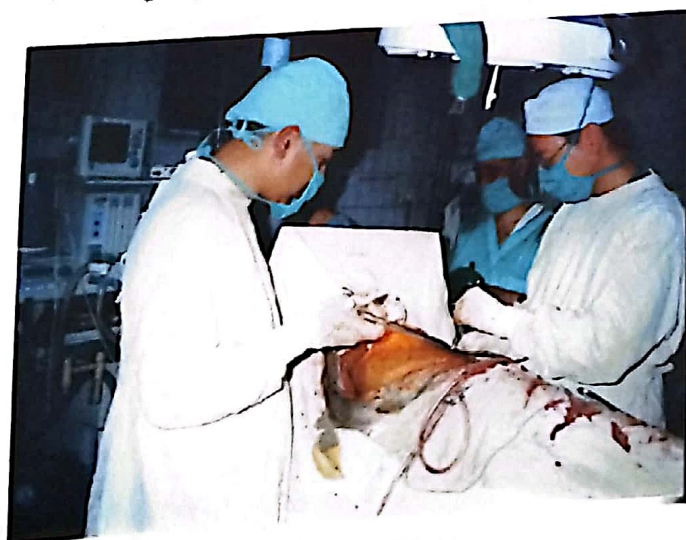## **List of Photographs**



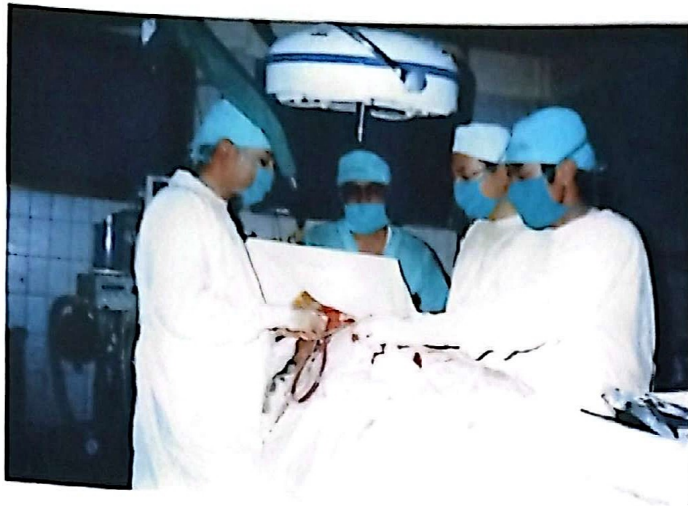**Questionnaires with hydatid patient**



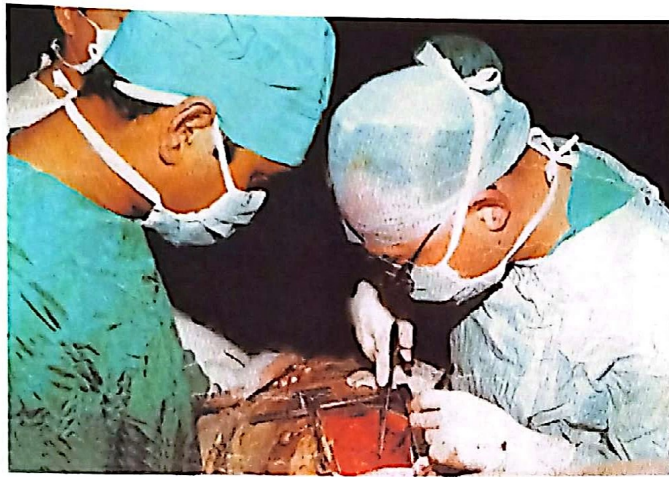
**During operation of hydatid cyst of lung**



**During hydatid cyst operation**



**Observation of hydatidosis operation**




**Hydatid disease operation in T.U.T.H, Maharajgunj**



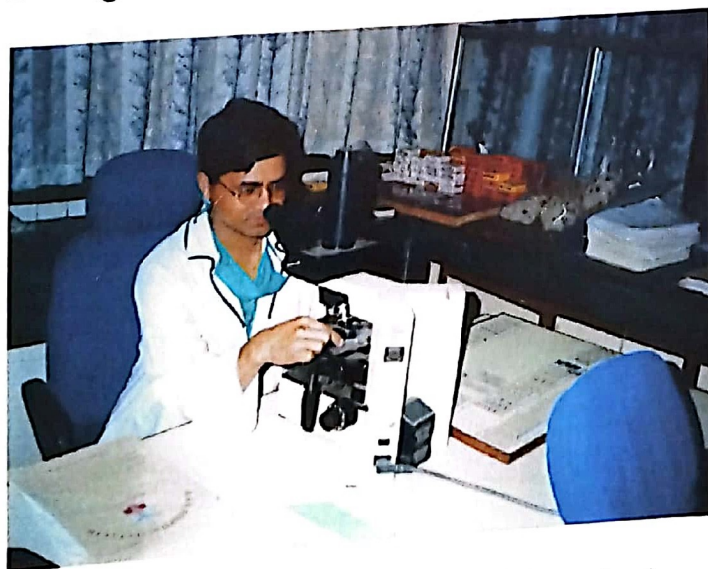
**One bowl contain hydatid cyst and another bowl contain right lung  
(Lobectomy)**



**Hydatid cyst of liver in bowl**

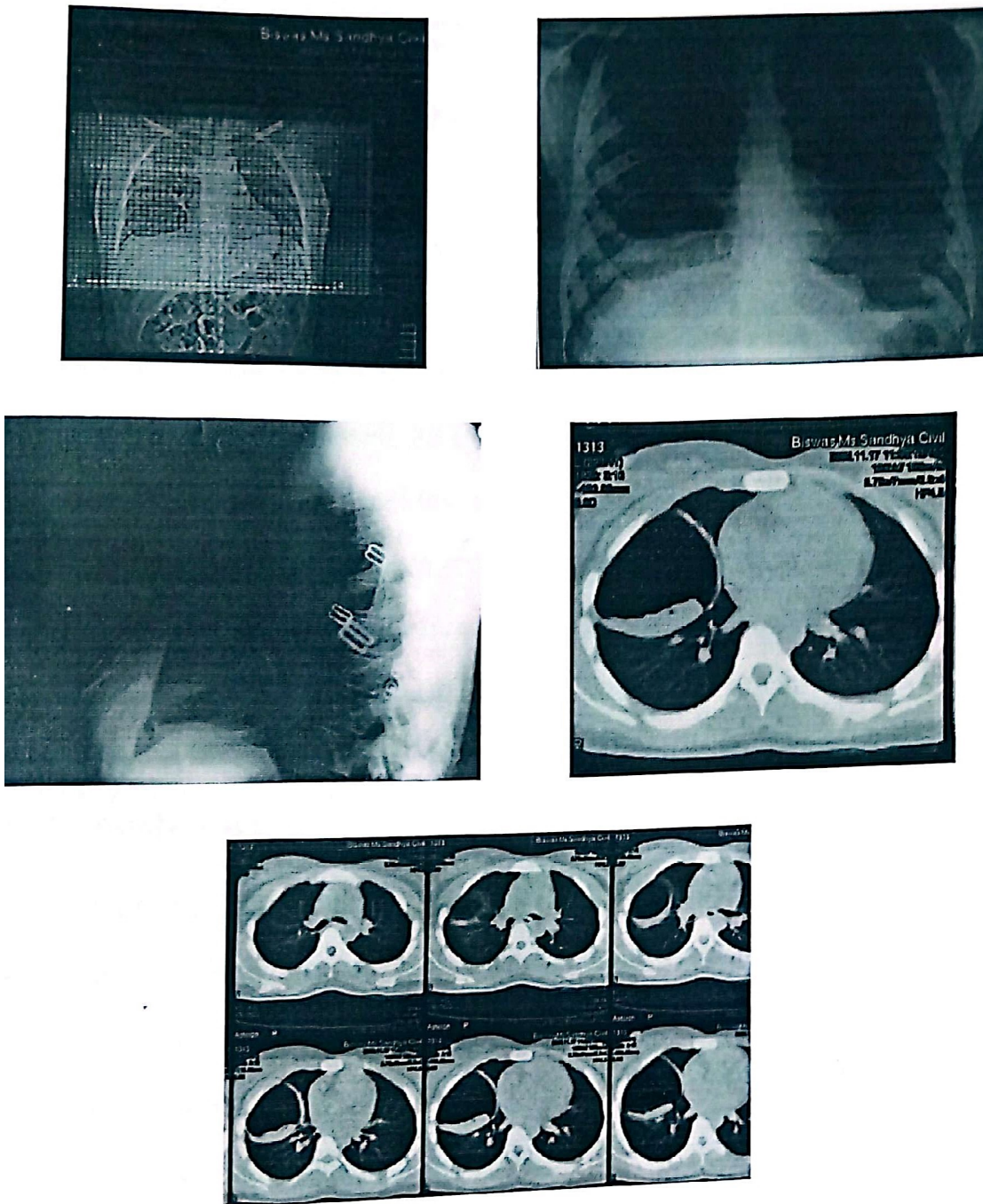


**During collection of hydatid cyst in laboratory**



**During observation of hydatid content**

**C.T. Scan Report:**



**Figure 3 C.T., Scan report of hydatidosis patient**

## CHAPTER-VI

### DISCUSSION

Hydatid disease caused by the larval stage of *Echinococcus granulosus* is endemic in many countries, including certain areas of American, European, Australia and Africa, mainly in sheep and cattle raising regions of the world. The disease is prevalent in most of the Asian Countries, like India, Pakistan, Afghanistan, Nepal Bhutan, Sri-Lanka and Bangladesh. Dog as well as other Canids, being the ideal host in which the adult parasite resides in the small intestine of the host (definitive hosts) and discharges numerous eggs (mortality) that come out with the faeces of definitive hosts. Other herbivorous animals including man get infected with this parasite when eggs are swallowed by means of water or food contamination and develop cyst in various parts of body mainly, liver, lungs as the larval form of the parasite.

All of the ethnic people in Hindu religion, worship dogs once a year during the Tihar festival. Although the majority of them are literate, they are unaware of hydatid disease infection in both dogs and human beings. So disease is prevalent among Hindus while Muslims were less commonly infected than Hindu (Schantz 1996).

Vogel (1955) considered leukarts informal designation for the alveolar type larval stage of *Taenia echinococcus* to be applicable and the cestode become known as *Echinococcus multilocularis*. In Tunisia, the sex ratio of infected children and youth (0-9 years of age) is approximately 1:1 however, among adults it is 1:2 (male:female) (Bchir et. al. 1987).

The National hydatid disease center of China (1992) reported, surgically confirmed cases of cystic hydatid disease in Xinjiang; 35% were in children under 15 years of age. Distribution of cases was similar among both sexes 49% were males and 51% were females.

Hydatidosis is one of the meat borne parasitic zoonotic disease spread in both pastoral and urban cycles, Ungulates, herbivores and human beings are the intermediate hosts of the cestode parasite *Echinococcus granulosus*, in which the metacestode stage develops in different organs forming unilocular cyst. After primary infection with the eggs of *Echinococcus granulosus*, metacestodes may develop in virtually any anatomical site of the human (Anamann R. et. al. 1995). Surgery is the preferred treatment when cysts are > 10 cm. diameter. Secondarily infected or located in certain organs i.e. the brain or heart (Schantz 1996).

The average number of cases reported each year is approximately 800 in Argentina, 550 in Uruguay and 225 in Peru. The annual cost of hospitalization, surgery, patient income losses.

In Nepal, Echinococcosis was first investigated by Joshi (1985). At that time echinococcal cysts were found in the buffaloes goats, sheep and pigs slaughtered in Kathmandu. In 1991 a preliminary study was conducted to document the prevalence of Echinococcosis in Kathmandu (Joshi 1992). In 77 small abattoirs, there was a 5% infection in water buffaloes, 3% in goats 8% in sheep and 7% in pigs, later on study carried out in western part of Kathmandu among the water buffaloes showed 21% prevalence of hydatidosis (Maharjan M. 1999).

*Echinococcus granulosus* is controllable in its domestic cycle by applying strong rabies control, proper waste disposal and meat inspection programmes which will give immediate benefits for human health (Joshi, 1985).

A study of an epidemiological assessment of echinococcosis in Nepal has reported 47 major surgical procedures done in valley group of hospitals in Kathmandu between 1985 to 1991 39% patients from Kathmandu. (Joshi et. al. 1996).

Hydatidosis is a wide spread problem through out the world including Nepal, until, recently only the effective treatment was surgery (Schantz 1996, Joshi et. al. 1996 and Rajbhandary 1998).

Present study revealed a total of 13 hydatidosis case in the age ranges from 4 years to 64 years, among them 8 (61.5%) were male 5 (38.46%) were female, 8 patients associated with lungs hydatid cyst and 5 had associated with liver hydatid cyst. All of them had operative removal of hydatid cyst, 6 patients had right sided hydatid cyst of lungs and 3 patient had left sided hydatid cyst of lung, one patient had bilateral hydatid cyst of lung and 5 patient had liver hydatid cyst. All the patients had unilocular hydatid cysts of liver and lungs. One patient had both right lung and liver hydatid cyst. For the removal of these cyst lungs hydatid cyst was operated by cardio-vascular thoracic surgeon by thoracotomy and liver hydatid cyst was operated by general surgeon by right Laparotomy method. In T.U.T.H. Maharajgunj, during this period 7 cases of hydatidosis associated with lung hydatidosis one patient with right lung and liver hydatidosis, were operated. In Bir Hospital all 5 patients with liver hydatidosis and one case observed in

B and B Hospital having right lung hydatidosis for this case Rt. lobectomy was done by cardiovascular thoracic surgeon. In T.U.T.H. among 7345 Major operated cases, hydatidosis case percent was 0.09% and in Bir Hospital among 6435 major operated cases 5 (0.07%) were due to hydatidosis during the study period.

In T.U.T.H. Maharajgunj among 7 hydatidosis cases, 5 were male (71.4%) and two were female (28.57%). All 7 patients were performed thoracotomy operation and one patient (14.2%) was performed both thoracotomy and laparotomy and in Bir Hospital all 5 cases was carried out laparotomy among them 3 were female (60%) and 2 were male (40%), hence total male. 8 (including B and B Hospital case also) and 5 were female.

During this period it was found that district wise hydatidosis distribution showed 5 (41.6%) was from Kathmandu and remaining 8 cases from other districts of country like Nawalparashi, Sarlahi , Lamjung and Kaski.

By age and gender wise distribution below age of 10 years number of infected patient was 4 (30.7%) among them 2 were male (25%) and 2 were female (40%). All of them have pet dogs, and use to play with dog and dog allowed to roam outside also.

The knowledge about zoonotic disease among operated patient showed average knowledge with 4 person (30.7%) and 9 (69.2%) person having poor knowledge about zoonotic disease. Among hydatidosis patients 2 person (15.3%) was vegeterian and 11 person (84.6%) was non-vegetarian. By this it proves that hydatidosis not only found in non-vegetarian, it also found in vegetarian too.

Among 13 hydatidosis patients, none of them had any knowledge about hydatidosis. The term itself is unfamiliar for them, most of them were only informed about accumulation of water in their liver or lungs and some of them heard about hydatid cyst only from physicians prescription.

Hydatid disease is encountered quite often in daily practice and is often diagnosed by radiography or ultrasonogram (Pathak et. al. 1989). The disease is being the public health problem in the world.

In Nepal diagnostic measures for hydatidosis includes imaging techniques eg. X-ray, USG, C.T. scan, M.R.I. available in T.U.T.H. but No. ELISA test available. In Bir Hospital, X-ray, U.S.G., C.T. scan available no. M.R.I., No. E.L.I.S.A. test. Due to lack of physician and surgeons out of valley in most of the district, the facility can not get by peoples. The E.L.I.S.A. test is only available in National zoonosis and food hygiene research center Tahachal Kathmandu.

The parasite cause hydatid disease in man. The conditions remains asymptomatic throughout the life in majority of the cases. It is detected only when cyst ruptures and gives anaphylactic reactions. The clinical manifestations of hydatid disease depend on the size, location and no. of hydatid cyst causes mechanical trauma, produces various pressure effects. The liver cyst causes abdominal pain, palpable abdominal mass, jundice and portal hypertension, in lungs produces dyspnoea and haemoptysis, asthma, pressure effect allergy.

Clinical symptoms: History of contact, local swelling, utricularial with fever, hydatid thrill, rapid inflammatory reactions of the surrounding tissue, osseous tissue weakened, infected organ enlarged (liver, lungs),

presence of cyst in brain or eyes may prove fatal, hydatid fluid contains toxins causes vomiting diarrhoea, abdominal pain, eosinophilia, pressure effect sometimes collapse.

The clinical manifestations of hydatid disease mimic a wide variety of illness. The clinical feature, of the disease is not characteristics Radio-diagnosis: X-ray is frequently helpful shows hallow like cysts a small rim of calcification. The hydatid cyst show non-calcified lesions. The U.S.G. and C.T. scan, M.R.I. are the recent radio-imaging procedures or value in the diagnosis of the hydatid disease. They show non-reactive (cold) cystic lesions in various organ and tissues.

The hospital data shows that the infection rate of hydatidosis in the human population is increasing and becoming serious problem for public health in Nepal. Among 13 patients, it was found that every patient contact with dogs, either pet or stray, most of them non-vegetarian, lack of awareness about disease, lack of prophylaxis, have no knowledge about hydatid disease. So, the hydatidosis increasing per year in Nepal comparing to the last years data (Annex-III, IV).

## CHAPTER-VII

### CONCLUSION AND RECOMMENDATION

#### 7.1 Conclusion

The human Echinococosis is a disease of major public health problem and economic importance in Nepal, the disease is scattered in different district of the country. Among 13 hydatidosis patients 8 were male (61.5%) and 5 were female (38.46%) with age ranges from 4 years to 64 years. Age and sex wise infection below age of 10 years 30.7% and productive age group between 21-30 years (23.07%) and 31.40 years (23.07%) remaining rest of age group. All the children have their own pet dogs and they allow their pet dogs to roam outside the household and they prefer to play with their dogs. Another risk factor regarding the use of raw vegetable and washing vegetables in natural water sources. In T.U.T.H. Maharajgunj among 7345 major operated cases, hydatidosis case was found to be 7 (0.09%) and Bir Hospital among 6435 major operative case, hydatidosis was found to be 5 (0.07%). In T.U.T.H. Maharajgunj, all 7 hydatidosis case was done thoracotomy, among them 5 were male (71.4%) and 2 were female (28.57%) and one 33 years male patient (14.2%) done right Thoracotomy and Laparotomy, and in Bir Hospital among 5 patients 3 were female (60%) and 2 were male (40%) all the case was done Laparotomy for removal of Liver hydatid cyst. By this it can be concluded that for the removal of Liver cyst Laparotomy was the choice and thoracotomy for removal of Lungs hydatid cyst.

All the operated cases in T.U.T.H. Maharajgunj and Bir Hospital were not residence of Kathmandu but 5 (41.6%) patients were from Kathmandu and rest of cases from other districts.

The findings of the study revealed that human hydatidosis was due to lack of knowledge about hydatidosis, meat borne disease, its transmission pattern public health hazard, the socio-economic condition, culture of the people unhygienic conditions, use of contaminated water to wash vegetable from river or pond which was not dog proof enhance greater opportunity for the transmission of hydatid disease.

Regarding diagnostic facilities, Imaging diagnostic facilities are sufficient and are in working condition in major hospitals of Kathmandu but rapid diagnostic facilities are found to be lacking such as serological testing like ELISA.

## **7.2 Recommendations**

### **“Prevention is better than cure”**

1. Preventing parasitic infection of dogs by regular deworming.
2. Prevention of dogs from eating infected offals of domestic animals (sheep, cattle, etc.) in the slaughter houses.
3. Strict Personal hygiene (e.g. such as washing hands after playing with or feeding the dogs.
4. Avoidance of unnecessary contact with infected dogs.
5. National strategy should be developed to reduce the human cases of hydatidosis by breaking the epidemiological cycle of infected dog-buffalos, sheep-dog, goat-dog-man.
6. Community educational advertisements through various communicational mass media (Television, Radio, Newspaper) must be put up regularly for mass awareness about hydatiodisis.
7. The mass sterilization of stray dog population by government should be implemented to stabilize dog population.
8. Serodiagnosis is facilities like ELISA test must be available for confirmatory diagnosis of cystic Echinococcosis in hospitals.

## REFERENCES

- Aknoglu A; Demiryurek, H. and Guzel; C., (1991). Alveolar hydatid disease of the liver, a report on thirty nine surgical cases in eastern Anatolia, Turkey. *American Journal of Tropical Medicine and Hygiene* 45; 182-89.
- Allan J.C. Craig P.S., Garcia Noval. J, Mencos, F, Liu, D. Wong, y, Wen, H., Zhou P., Stringer, R. Rogan, M.S. Zihyle E. (1992). Coproantigen detection for immunodiagnosis of echinococcosis and taeniasis in dogs and humans. *Parasitology*, 104, 347-335.
- Altintas, N., (1998). Cystic and alveolar echinococcosis in Turkey. *Annals of Tropical Medicine and Parasitology* 92 (6) Sept: 637-642.
- Anamann R. and Eckert J., (1995). *Clinical diagnosis and treatment of echinococcosis in humans*. In Echinococcus and hydatid disease CAB international, wallingford, England, PP. 414-463.
- Angulo, J. C., Escribano J. Diego, A; Sanchez, M.C., (1998). Isolated retroversical and extrarenal retroperitoneal hydatidosis: Clinical study of 10 cases and literature, review *Journal of Urology* 159 (1) 56-82.
- Baronet, D. Toews, D. W. craig, P.S. and Joshi, D.D., (1993). *Echinococcus granulosus* infections in dog population of Kathmandu Nepal. National zoonoses and food hygiene Research center, Tahachal Kathmandu Nepal.

- Bchir, A., Jalen A., Jemmali, M. Rousset, J.J. Gaulebout, C. Larouze, B. (1987). Possible existence of an Urban Cycle of *Echinococcus granulosus* in central Tunisia. *Transactions of the Royal Society of Tropical Medicine and Hygiene*: 81, 650.
- Bengisun, U. Gunduz, J. Junc, M., Kesenci, I., Kunzu, S. D., Belent, A., (1997). Surgical treatment of advanced alveolar hydatid disease of the liver (A Report of Five Cases surgery Today (Tokyo) 27 (3): 261-265.
- Bitkowska, E. Elzbieta G. Wojciech, P. Tadeusz H.D. (1997). Application of the western blot method to the serological diagnosis of hydatidosis in poland. *Medycina Doswiadczalna i mikrobiologia* 49 (3-4): 215-223.
- Boeva J; Todorov, T. Petkov, A. Nedekhav, and Zhelluskov, P., (1993). Epidemiology of hydatid disease in Bulgaria. *International Archives of Hydatidology* 31,105.
- Boeva V., (1977). Epidemiological characteristics of Echinococcosis in some regions of Bulgaria. *Letopissy of hygiene epidemiological stations*, 5: 146-151.
- Boeva V., (1982). Studies on the dynamics of human echinococcosis in Bulgaria. In (Abstracts) Fifth national congress on infections and parasitic disease, 8-10. October 1982: 162-163.
- Boeva-Bangiozova V., (1979). Studies on seroepidemiology and dynamics of distribution of human echinococcosis in Bulgaria. Ph. D. thesis, sofica, institute of infections and parasitic diseases.

- Carthy M. C., (1957). The epidemiology of *echinococcus granulosus* in Newzealand. *National Environmental Newzerland Medical Journal*, 56:206-212.
- Craig P.S., (1993). Medical Parasitology, A practical Approach Chapter 11, P.2
- Craig, P.S., Eshan D.L. and Zhaoxum D. (1991). Hydatid disease in China, *Parasitology Today* 7, 46-50.
- Davis A., Dixon H., Pawlowski Z. (1989). Prulticentre clinical trials of benzimidazole carbamates in human cystic echinococcosis (Phesez). *Bulletin W.H.O.* 67: 503-508.
- Dey C.N. and Dey K.T., (First edition). *Medical Parasitology*, New Cental Book Agency (P). Ltd. 8/1 Chintamoni das lane Calcutta 700009.pp. 9.1, 1-9.15
- Diesing (1863). In rublic of panama. *Annals of tropical Medicine and Parasitology* vol; 63, 165-75.
- Eckert, J. and Thompson, R.C.A., (1997). Intraspecific Variation of *Echinococcus granulosus* and Related Species With Emphasis on Their Infectivity to Human *Acta Trapica* 64 (1-2): 19-34.
- Erdener, A., Ozok A, Demiccan, M., (1992). Surgical treatment of hepatic hydatid disease in children. *Europ J of Ped surgery.* 2 87-89.
- Essadi, M.A, Raji A., Laraqui Z.N., Kadiri F. Touhami M. (1999). Hydatid cyst of the thyroid gland (Three case reports). *Semaine des Hospital* 75 (11-12) 1-8: 330-333.

- Fillce, C.F. Pirola, E. Brunetti, (1990). A New the rapeutic approach for hydatid cyst of liver. *Gastroenterology* 98: 1366-1368.
- Golaszewski, T., susani M., Sliutz G., Auer H. (1995). A large hydatid cyst of liver in pregnancy. *Archives of Gyanecology and Obstetries* 256 (1): 43-47.
- Hao and Wen-Guang; (1997). Public Health Importance of Cystic Echinococcosis in China. *Acta Tropica* 67 (1-2): 133:145.
- Hao W. Craig P.S. (1994). Immunoglobulin G subclass response in human cystic and alveolar echinococcosis. *American Journal of Tropical medicine and Hygiene* 51 (6): 741-784.
- Hendrickson, D.A., (1985). Reagents and stoins P. 1093-1107. In E.H. Lennette, A. Balows W.J. Hausler Jr. and H.J. shadomy (ed)' manual of clinical microbiology, 4<sup>th</sup> ed. *American society for microbiology, Washington D.C.*
- Hira, P.R., shwelici, H., Lindberg L.A., (1988). Diagnosis' of cystic hydatid disease role of aspiration cytology, *Lancet* ii: 655-657.
- Horton R.J., (1989). Chemotherapy of *Echinococcus* infection in man with albendazole. *Trans Roy Soc Trop. Med. Hyg.* 83:97-102.
- Ingram, E.A., and Helikson, M.A., (1991). Echinococcosis (hydatid disease) in Missouri: diagnosis by fine needle aspiration of a lung cyst. *Diagnostic cytopathology* 7:527-531.
- Joshi A.B., Joshi D.D., Schantz P.M., Joshi H. and wald Alan., (1996). Epidemiological assessment of Echinococcosis in Nepal.

- (Abstract), National Seminar on echinococcosis / hydatidosis organized by N.Z.F.H.R.C. and I.D.R.C. Ottawa Canada.
- Joshi D.D., (1992). Epidemiological study of Echinococcosis / Hydatidosis in human and animals of Kathmandu, Nepal. Report to I.D.R.C. Ottawa, Canada, April, 1992.
- Joshi D.D., Schantz PM, Craig P.S. and Bhatta D.R., (1995). Diagnosis of cystic echinococcosis / hydatidosis in human by clinical imaging Techniques and serology. Proceeding of National Seminar on echinococcosis / hydatidosis Jan, 23-24, 1996, Kathmandu Nepal, 49, 48-53.
- Joshi, D.D., (1985). Surveillance of Echinococcosis / Hydatidosis in animals and humans of Kathmandu, Nepal. Report on WHO Supported Project on epidemiological surveillance of humans and animals for echinococcosis / hydatidosis.
- Kahalil, A., Bairds Smith M., Maclean D, Poenaru, D., Barkun N., (1996). Acute Cholecystitis and Choleangitis caused by Echinococcus granulosus. *American Journal of Gastroenterology*. 91 (4): 805-807.
- Karawi, Al., Mohamed S. El. and yasaway, M.I., (1990). Advances in diagnosis and management of hydatid disease *Hepato-gastroenterology* 37:327-331.
- Karim D.F. and Alkarmi T., (1997). Immunopathology of Alveolar Echinococcosis; *Acta Parasitologica* 42 (1): 1-6.

- Karim, D.F. & Alkarmi T., (1997). Public health Aspect of Cystic echinococcosis in the Arab Countries. *Acta Tropica*, 67 (1-2): 125-132.
- Khuroo, M.S. wani, N.A., Javid. G., (1997). Percutaneous drainage compared with surgery for hepatic hydatid cyst. *N. Engl. Journal Medical* 337:881-887.
- Lightowiers, M.N., and Gottstein, B., (1995). Echinococcosis / hydatidosis, Antigens immunological and molecular diagnosis. In *Echinococcus and hydatid disease* CAB international, wallingford England, PP. 355-410.
- Madori A., Adachi K., & Akira Ohkawara (1999). Post-operative alveolar hydatid disease with cutaneous - subcutaneous involvement. *Journal of Dermatology* (Tokyo) 26 (6) 343-347.
- Maharjan M., (1996). "Incidence of zoonotic disease: Echinococcosis/hydatidosis in water buffaloes slaughtered for meat in western part of Kathmandu. (M.Sc Thesis) Central Department of Zoology, T.U.
- Mendez Montero, J.V., Garica J. A., Antela J. Lopez A. (1996). Fat Fluid level in hepatic hydatid cyst: A new sign of rupture into the biliary tree. *American Journal of Roentgenology* 167 (1): 91-94.
- Metossian, R.M., Richard, M.D. and Smyth J.D. (1977) Hydatidosis a global Problem of increasing importance. *Bulletin of the World Health Organization* 55, 499-507.

- Morris D.L., (1980). The management of hydatidosis. *British Journal Hospital Medicine* 24:586-595.
- Morris DL, Richards KS., (1992). Hydatid disease current medical and surgical management Oxford, Butterworth-Heinemann ZTD, 150 pp.
- National Hydatid Disease Center of China., (1992). Retrospective survey of surgical cases of cystic hydatid disease in xinjing (1950-1990) *Endemic Disease Bulletin* 7, in press.
- Ockenga, J. Gebel, M., Caselitz M., Bleck, J., (1998). 3D Ultrasound in imaging diagnosis and follow up of an atypical hydatid cyst. *Manuals Zeitschrift Fuer Gastroenterologic* 36 (7): 599-603.
- Olcay, L., Aytakin B., Mehmet E., Ayhan G., Aytemiz G., (1998). Hydatid cyst mimicking pulmonary hematoma in a patient with haemophilia. *Turkish Journal of Pediatrics* 40 (3) September: 425-429.
- Pandey V.S. Ouhelli H. and Moumen A., (1988). Epidemiology of hydatidosis / echinococcosis in ouarzazate, the Saharan region of Morocco. *Annals of tropical medicine and parasitology* 82, 461-470.
- Parija C. Subash., (First edition). Text book of Medical Parasitology, Protozoology and Helminthology, All India publishers and distributors, Regd. Madras – 600084, pp. 213-218., Pathak (1989).
- Petkov A., (1976). Status and future measures against echinococcosis and other cestodes. *Veterinarna* 2:29-32.

- Petkov A., (1990). Organization of the echinococcosis control programme in Bulgaria *Boletin de hydatidosis* 18:23-28.
- Petkov A., (1997). Analysis and critical evaluation of the control measures against echinococcosis in Bulgaria. *Sarremena medicina*, pp. 48:3-5.
- Piekarski G., (First edition) *Medical Parasitology* of the institute of medical parasitology university of BONN pp. 95-102.
- Primo A., (1997). Public Health Importance of Cystic Echinococcosis in Latin America, P. 67 (1-2): 113-124.
- Rai, S.K., Shrestha, H.G., (1996). Diagnostic approaches of hydatidosis: An overview. Proceeding of the National Seminar on echinococcosis / hydatidosis January 23-24, Kathmandu,
- Rajbhandary G.L., (1995). Hydatid cyst complete resolution following Albendazole treatment *Nepal Medical Association* 33:131-132.
- Rajbhandary G.L., (1998). Hydatidosis: A cystic disease of lungs and liver spread to human by infected dog. *Medical Journal of Shree Birendra Military Hospital* 1:1, 32-34.
- Rajbhandary G.L., (1998). Surgical experience with hydatid cyst of lungs and liver. *Journal of society of surgeons of Nepal* 1:1, 13-15.
- Ratala D.R. Craig P.S., Joshi D.D. Baronet D., (1996). Immuno diagnosis of echinococcosis in dogs by use of coproantigen detection techniques proceedings of National Seminar on echinococcosis / hydatidosis Jan, 23-24 1996. Kathmandu, Nepal.

- Rombert C. and Trinica, T., (1991). Immunodiagnosis of human hydatidosis in Portugal. *Archivos data hydatidosis* 30, 993-999.
- Sammak, B., Youssef, A. Rahman, Begi A., Shahed Al. M, Marawi Al. M., (1999). Radiological manifestation of liver and gastrointestinal parasitic infections. *Hepato-gastroentology* 46 (26) March, April: 1016-1025.
- Sapkas G. S., Dimitrios P., (1998). Described hydatid disease of bones and joints: 8 cases followed for 4-16 years. *Acta orthopaedica scandinavica* 69 (1) Feb: 89-94.
- Schantz, P.M. (1996) Epidemiology of cystic echinococcosis: Global distribution and patterns of transmission. *Proceedings of National seminar on echinococcosis / hydatidosis Janaury* 23-24, 1996 Kathmandu, Nepal.
- Schoresanitis G., E. de Bree, Medissas J., Tsiftsis D., (1998). Primary hydatid cyst of the adrenal gland. *Scandinavian Journal of Urology and Nephrology* 32 (1) Feb: 31-33.
- Schwabe cw., (1968). Epidemiology of echinococcosis. *Bulletin of the world health organization*, 38:700-704.
- Shambesh, M.K., Machperson, C.N.L. Beesly, M.N. Gusbi, A. and Elsonosi traitment., (1992). Prevalence of hydatid disease in North western Libya: a cross – sectional ultrasound study. *Annals of tropical medicine and parasitology*, 86, 381-386.
- Sharma M. C., Asis K. Karak, (1998). Primary hydatid cyst of the breast A case report. *Surgery Today (Tokyo)* 27 (12) 1188-1190.

- Sood R. (First edition) *Parasitology (Protozoology and helminthology)*  
CBS publishers and distributors 485, Jain Bhawan, Bhola  
Nath Nagar, Shahdara, Delhi 110032 (India). Pp. 194-196.
- Stallbaumer M.F. Clarkson, M.J. Bailey, J.W. and Pritchard, J.E. (1996).  
The epidemiology of hydatid disease in England and Wales.  
*Journal of Hygiene (Cambridge)*, 96, 121-127.
- Thompson, RCA and Hymbery AJ., (1995). *Echinococcosis and hydatid  
disease* CAB international Wallingford, England, pp. 355-463.
- Todorov T., (1967). Studies on echinococcosis in Bulgaria: Spread of  
echinococcosis in population. *Saveremena medicina*, 18:124-133.
- Todorov T., (1968). Studies in three districts of south Bulgaria, Ph. D.  
Thesis, Sofia, Research Institute of Epidemiology and  
Microbiology *Bulletin of the W.H.O.* 77 (2).
- Todorov T., and Boeva, V., (1992). A comparative epidemiological  
analysis of Human Echinococcosis in Bulgaria. *Bulletin of  
the World Health Organization* 77 (2): 110-118.
- Valchos, J.D; and Zachariadou S., (1972). Microscopic structure of  
*Echinococcus granulosus* miniature scolices. Birefringence  
*Arch. Pathology.* 93:246-247.
- Valladares D.L, Sanchez A. L., (1998). Hydatid liver cyst perforation into  
the digestive tract. *Hepato-Gastroenterology* 45 (24): 2110-  
2114.
- Vogel, H., (1955). über den Entwicklungszyklus und die Artzugehörigkeit  
des europäischen Alveolar Echinococcus. *Deutsche  
Medizinische Wochenschrift* 80; 931-2.

W.H.O., (1980). Hydatidosis control (Mediterranean countries) Report on a W.H.O. meeting, October, 13-15, 1980, Fez (ICP/BVM 009, 554113), Geneva World Health Organization.

W.H.O., Report of the working Group meeting on clinical medicine and chemotherapy of alveolar and cystic echinococcosis Besancon, France, 10 October, 1992.

Yalcinkay, L., Ugas S., (1999) Surgical treatment of hydatid cyst of the lung: Liver of 30 cases. *European Respiratory Journal* 13 (2): 441-444.

Young, T.H., Tsai Y. H., Yao C. L., You C. C., Heng S. L., Hung S.T. (1996). Hydatid cyst in the liver. *Journal of the Formosan Medical Association* 95 (2): 176-179.

## ANNEX-I

### Questionnaire

#### I. Questionnaire for hydatid patient and their family people:

(1) Name

Age:

Sex:

Address:

(2) Do you have knowledge about hydatidosis or zoonotic disease?

(a) good      (b) average      (c) poor

(3) Do you have pet dog?

(a) Yes      (b) No

(4) Do you allow your dog to roam outside?

(a) Yes      (b) No

(5) What type of meat, the dog is fed?

(a) cooked      (b) uncooked      (c) Bone

(d) skin      (e) fat bodies

(6) Do you allow children playing with dog?

(a) Yes      (b) No

(7) If children playing with dogs after that they wash hand thoroughly or not?

(a) Yes      (b) No

(8) How many stray dogs are in you village or town?

- (9) Stray dog problem?  
(a) Yes (b) No  
If yes elaborate
- (10) Do you know dogs can transmit many disease to human beings?  
(a) Yes (b) No
- (11) What was dog owner's knowledge about hydatidosis?  
(a) good (b) average (c) poor
- (12) What type of dishes do you consume?  
(a) Vegetarian (b) non-vegetarian (c) both
- (13) If non-vegetarian which type of meat usually consume?  
(a) sheep, (b) goat, (c) buffalo, (d) pig
- (14) If vegetarian which type of water use for wash vegetable?  
(a) pond (b) river (c) tap
- (15) Do you have cattle pet?  
(a) Yes (b) No
- (16) If yes, what type of?  
(a) sheep (b) goat (c) buffalo (d) pig
- (17) Where do you bring them for grazing?  
(a) open grass ground (b) farms (c) special grazing ground  
(d) only inside your compound (e) other
- (18) Is the cattle grazing place dog proof?  
(a) Yes (b) No

## ANNEX-II

### Hydatidosis Operation in T.U.T.H., Maharajgunj, and Bir Hospital During June 1999 to July 2000.

Name of patient	Age	Sex	Pre operative diagnosis	Operation
T. B. Thapa	9	M.	B.L. cyst of appear in lungs	Thoracotomy
T. Rana	33	M.	Cyst appear in Rt. lung & Liver	Thoractomy with laparotomy, removal of cyst
P. Maharjan	4	F.	Cyst appear in Rt. lung	Thoracotomy, removal of cyst
S. Adhikari	10	M.	Cyst appear in Rt. lung	Thoracotomy, removal of cyst
N. Lama	35	M.	Cyst appear in Left lung	Thoracotomy, removal of cyst
S. Ale	6	F.	Cyst appear in Rt. lung	Thoracotomy, removal of cyst
S. B. Kund	40	M.	Cyst appear in left lung	Thoracotomy, removal of cyst
R. P. Khanal	64	M.	Cyst appear in liver	Laparotomy, removal of cyst
R. B. Thapa	21	M.	Cyst appear in liver	Laparotomy, removal of cyst
R. Bom	42	F.	Cyst seen in liver	Laparotomy, removal of cyst
G. Devi	24	F.	Cyst seen in liver	Laparotomy, removal of cyst
B. S. Nepali	16	F.	Cyst appear in liver	Laparotomy, removal of cyst
S. Gurung	24	M.	Cyst appear in lung	Thoracotomy with Lobectomy

### ANNEX-III

#### Public Health Problems

#### Hydatid Cases in Bir Hospital

Year	Major operated cases	Hydatidosis	(%)
1985	1934	2	0.10
1986	1439	5	0.34
1987	1360	6	0.44
1988	1445	1	0.06
1989	1647	3	0.18
1990	1825	2	0.11
1991	3455	6	0.17
1992	2916	2	0.06
1993	3899	5	0.12
Total	19920	32	02

## ANNEX-IV

## Hydatid Cases in T.U.T.H., Maharajgunj

Year	Total major operated cases	Hydatidosis	(%)
1985	442	4	0.90
1986	1650	1	0.06
1987	3319	2	0.06
1988	3720	6	0.16
1989	4220	4	0.09
1990	4212	3	0.07
1991	4715	2	0.04
1992	5062	1	0.01
1993	5798	2	0.042
Total	32138	25	1.43

## ANNEX-V

### Geographical Distribution of Human Hydatid Cases

(N.Z.F.H.R.C. Report)

Kathmandu	9	39%
Dhading	1	4%
Kailali	2	8%
Bhaktapur	2	8%
Bhojpur	1	4%
Tanahu	1	4%
Kabhre	3	12%
Dolakha	1	4%
Bharatpur	2	8%
Makawanpur	1	4%
Total	23	100%