

1. INTRODUCTION

1.1 Background:

The Crocodylians are the earliest reptiles that were existed as the same time as dinosaurs. At present there are 23 species of crocodiles in the world (Whittaker and Basus 1983); all of them are regarded as endangered species and are widely distributed in most of the tropics and subtropics part of the world. The Order Crocodylia, which includes all living crocodylians, originated around 100 million years ago (mid-cretaceous) (St. John et al. 2012). Crocodylians and birds are the only living representative of the ancient group Archosauria, which included dinosaurs and pterosaurs (St. John et al. 2012). In Nepal only two species of crocodiles are found; the Gharial, *Gavialis gangeticus* and the Mugger, *Crocodylus palustris*. A very early gharial- like fossil was reported from the Morocco's 60 million years-old rocks (Hua and Jouve 2004). Although 12 fossil species have been found in India, South America, Africa and Europe; only one species survives today. The term "Gharial" originates from hindi word "Ghara" which means a clay pot with long neck that is very much similar to the snout of an adult male gharial.

The average size of mature gharials ranges from 3.5 to 4.5 m. The maximum recorded size was 6.25 m. While the hatchlings measures approximately 37 cm. The young gharials can reach a length upto 1m in eighteen months. The average body weight of an adult gharial measures from 159-181 kg. Males can reach up to 6m while females are smaller and can reach a body length of 3.75 m. Their jaws are lined with many interlocking, razor like sharp teeth; 27 to 29 upper and 25 or 26 lower teeth on each side. These teeth are not arised from the interdental pits. They have well-developed laterally flattened tail and webbed rear feet that helps to adapt in the deep and fast flowing water habitat. But on land they only can push itself forward and slide on its belly. Its elongated and narrow snout becomes proportionally shorter and thicker as the animal matures. They are sexually dimorphic animal; the male has bulbous growth on the tip of the snout while that is absent in female.

They are found in Northern Indian subcontinent in river drainages: India, Pakistan, and Nepal. Their numbers are very low or extinct in Bangladesh, Bhutan, and Burma. The most important remaining populations occur in three tributaries of the Ganges River: Girwa and Chambal Rivers in India, and Rapti-Narayani River in Nepal (Whitaker 1987).

1.2 Gharial conservations:

Gharial was placed on the 1st Appendix of the CITIES list as an endangered species but the huge habitat loss and the great decrease of gharial population in its whole distribution change the status in 2007. Gharial is now listed as an extremely endangered species in the IUCN Red list.

Gharials spend most of their time in the water where they find all their food and they use the sand banks to bask and make nests. As they use to return every day on the same place to bask; any modification in these habitats is extremely dangerous for their survival rate. Poaching, habitat destruction, pollution, river poisoning, sand mining, disturbance by people, heavy commercial net-fishing, predators of eggs, dams and diseases are the great threats for their survival.

The first consideration on gharial was edited by the crocodile specialist group in March 1971 which expressed a major concern on this animal (Das 1981). India and Nepal listed the Gharial on their protected species list. At the same time, India built a breeding center with the help of FAO & UNDP. Since, this date, about 3000 young gharials were released in 12 different rivers; the major released program was done in Chambal river (India) where, 1718 individuals were released during the period 1979-1993 (Ross 1998).

Gharial conservation began in 1971 in Nepal with the help of the Frankfurt Zoological Society. It is based on population reintroduction by egg collections, gharial breeding and juvenile release. Until now, nearly 700 individuals were released in four different rivers of Nepal (Andrews and Mc. Achnar 1994, DNPWC 2005). There is no fixed regular monitoring programme for gharials as done for mammalian fauna which is very much essential for their comparative studies and necessary steps for their conservations.

1.3 Gharial diseases:

Crocodiles suffers from many health problems during various stages of its life; egg, embryo, juveniles (hatchlings) and adult stages. Various types of transmissible, non-transmissible, organ diseases and miscellaneous conditions are found in the crocodiles. The shell of eggs plays a vital role for the protections of the developing embryo and exchange of gases from external environment. It was found that American alligator eggs with early embryonic mortality have a lower degree of shell porosity and the pores were plugged by undetermined material when compared with the shells of eggs with normal embryonic development (Wink et al. 1990). Various types of shell defects in *Crocodylus porosus* eggs; soft shells, partial shell formation, complete absence of shell with only the membrane being present, additional calcareous protrusions on the external surface of the shell, under or oversized eggs and eggs of deformed shape with incomplete sealing were found (Hibber 1996). Early embryonic deaths can also be caused due to improper handling of banded eggs which can dislodges the embryo form its attachment to the shell and lets it sink into the yolk sac. The wild eggs should be collected until the embryos are at least four weeks old (Blake 1992). The gharials raised in captivity are susceptible to various gastrointestinal and mycotic infections. The major gastro-intestinal parasites reported in gharials and other crocodiles are: *Corynebacterium* spp. (Arora and Kumar 1985-1989, Mishra et al. 1993, Mehrotra et al. 2000, Gairhe 2007), *Pseudomonas aeruginosa* and *E. coli* (Shotts 1981, Arora and Kumar 1985-1989, Foggin 1987, Ladds and Sim 1990, Mishra et al. 1993, Huchzermeyer et al. 1994, Chakraborty 1995, Mehrotra et al. 2000, Gairhe 2007), *Aeromonas* spp. (Mishra et al. 1993, Maskey et al. 1998, Gairhe 2007), *Edwardsiella tarda* and *Haffnia* (Mishra et al. 1993, Gairhe 2007), *Staphylococcus aureus* (Mishra et al. 1993, Mehrotra et al. 2000, Gairhe 2007), *Mycoplasma* spp. (Mishra et al. 1996), *Providencia* spp. (Sinha et al. 1987, Hawake 2002, Gairhe 2007), *Eimeria* spp. (Gardiner 1986, Levine 1987, Aquino-Shuster and Duszynski 1989, McAllister and Upton 1990) and other coccidians (Huchzermeyer 2002, Lads 2003, Gairhe 2007).

Neodiplostomum gavialis a trematode (Narain 1930), *Exotidendrium gharialii* (Mehera 1935, Deblock et al. 1965), *Acanthostomum elongatum* and *A. atae* (Tubangui and Masilungan 1936), *Pseudoneodiplostomum bifurcatum* (Deblock et al. 1965), *Pseudoneodiplostomum thomasi* (Deblock et al. 1965), *Renivermis* spp. (Blair et al. 1989), *Acanthostomum americanum* (Vigueras 1956), *Pseudoneodiplostomum groschafti*,

Pelazia loosi and *Telorchis* spp. (Moravec et al. 2001), *Timonella absita* (Blair et al. 1988), *Polycotyle ornate*, *Acanthostomum coronarium*, *Archaediplostomum acetabulum* and *Pseudocrocodicola americana* (Hazen et al. 1978), a cestode (Ladds and Sims 1990), *Micropleura viviparous* (Linstow 1906), *Typhlophoros lamellaris* and *Procephalus indicus* (Ladds 2003), *Dujardinascaris helicina* (Molin 1860), *Ascaris helicina* (Baylis 1947, Sprent 1977), *Contracaecum* spp. (Rudholpi 1819, Drasche 1882, Stossich 1890, Hollis et al. 1939), pentastomid *Sebekia* spp. (Sambon and Giglioli 1922, Rogers et al. 1971, Riley and Huchzermeyer 1995, Spratt et al. 1990), *Alofia* spp. (Lohrmann 1889, Von Linstow 1906, Giglioli 1922, Riley and Huchzermeyer 1955), *Leiperia* spp. (Vaney and Sambon 1910, Diesing 1936, Riley and Huchzermeyer 1996) and *Subtriquetra* spp. (Diesing et al. 1836).

1.4 Objectives of the study:

1.4.1 General objective:

- To isolate and identify the gastrointestinal helminth parasites of captive Gharials (*Gavialis gangeticus*) hatchlings at Chitwan National Park.

1.4.2 Specific objectives:

- To isolate and identify the gastrointestinal parasites of gharial hatchlings.
- To determine the prevalence of gastrointestinal helminth parasites in gharial hatchlings.
- To study the relationship between age of the gharial hatchlings with parasitic infections.

1.5 Significance of the study:

Gharial hatchlings are highly sensitive and are prone to various health hazards. Various parasites can easily derange their physiological activities and can lead to their death which is one of the challenging factors for their successful captive breeding. Among these parasites, gastrointestinal helminth parasites are the one which are responsible for high mortality rate in captive gharial breeding. The present study was focused to reveal and identify various gastrointestinal helminth parasites, which will be helpful to control high mortality rate in captive gharial by identifying their source and proper medical treatments.

2. LITERATURE REVIEW

Besides various types of bacterial, protozoal and fungal infections, crocodiles have also gained various types of helminthic infections. Various parasitological investigations were conducted in various parts of the world where crocodiles are found. Among crocodilians, Gharials has also been badly affected by the various species of helminth parasites. Since, the Gharial feed upon the fishes it is one of the most important route for the transmission of the different stages of helminth parasites. Due to lack of sophisticated technology, easy access and easy availability of the samples for the research still the parasitological investigation is not sufficient and lagging behind.

2.1 Helminth parasites of crocodile:

2.1.1 Global context:

2.1.1.1 Trematodes:

A digenean trematode, *Timonella absita* (Blair et al. 1988) belonging to the family Cryptogonimidae was reported from the small intestine of salt water Australian crocodile, *Crocodylus porosus*. Although, the species was closest to *Timonella unami* and *Timonella loosi*, but differs in the number of oral spines and the posterior extent and in arrangement of the vitelline follicles. Its body was cylindrical with average 2.72 x 0.5 mm and tapering towards posterior end. Eye spots and tegumental spines were not seen. Similarly, oral spines 0.06-0.07 mm were long, 0.014-0.018 mm in basal width, oral sucker were terminal and were funnel shaped. The caeca were simple, lateral and were extended upto posterior end of the body; testes were tandem, irregularly ovoid and intercaecal in posterior quarter of body and ovaries were transversely ovoid and not contiguous with anterior testis.

In a study (Mehera 1935), a digenean trematode *Exotidendrium gharialii* was reported from the Indian gharial, *Gavialis gangeticus*. The trematodes of this genus were obtained in large numbers from the rectum near the cloaca. About 25% of the hosts were found to be infected with these parasites. These parasites were very minute, elongated with narrow neck capable of great extension and contraction and were slightly rounded at the posterior end. Due to the high capacity of contraction and relaxation it exhibits various types of

shapes. Its cuticles were armed with small pointed spines which becomes sparse behind the ovary and were absent in the hinder part of the body. Ovary post-testicular and posterior position of vitellaria is the characteristics features of these parasites.

Acanthostomum elongatum and *A. atae*, the digenetic trematodes (Tubangui and Masilungan 1936) were reported from the intestine of Philippine crocodile, *Crocodilus mindorensis*. Their body differs in the length, number of cephalic spines, position of vitellaria and size of the eggs. Both of this species belongs to the family Acanthostomidae (Poche 1925). The members of the genus *Acanthostomum* were the parasites of the fishes and reptiles (Loss 1899).

Similarly, another digenetic trematode, *Paraoistosomum novaeguineae* (Tkatch 2011) from the kidney of New Guinea crocodile, *Crocodylus novaeguineae* of Papua New Guinea. This new species of parasite strongly resembles with the *Oistosomum caduceus* (Odhner 1902), the single member of *Oistosomum*, a genus without clear phylogenetic relationships and systematic position that was described from Sudan in 1902 and never reported till. Besides this, parasites differs in having shorter intestinal caeca, relatively large ventral sucker, ovary anterolateral to ventral sucker, vitellaria arranged in two clusters and longer oesophagus.

A total 45 specimens of the trematode, *Neodiplostomum gavialis* from the duodenum and small intestine of single crocodile (*Gavialis gangeticus*) about 5 feet long was reported by Narain in 1930. The worm belongs to genus *Neodiplostomum* (Raillet 1919), of the sub family Polycotylineae and Family Strigeidae (La Rue 1926). The parasites were 3.5 to 4 mm in length and 1 to 1.5 mm in breadth. These whitish parasites were provided with the two deep brownish streaks on the sides which marks the intestinal caeca. The mouth was terminal and was surrounded by oral sucker and muscular pharynx with short oesophagus that bifurcates to form the intestinal caeca. The ovary was oval, dorsal, and was present near the caudal region of the body while the testes were large and situated at the middle of the caudal region.

Based on 20 specimens (Viguerus 1956) collected from the three young Morelet's crocodiles, *Crocodylus moreletii* located in Yucatan, Mexico, the trematode, *Acanthostomum americanum* of the family Acanthostomatidae (Poche 1925) was described. The body of gravid specimens were 1.589-3.371 mm in length and 0.0517-0.666 mm in width; body surface were covered with spines; oral sucker terminal and were

funnel shaped; ventral sucker circular; intestinal branches run along body to caudal end; intestinal bifurcatum in front of ventral sucker; testes tandem or slightly diagonal and were located nearby posterior end of the body; Ovary transversely oval and was smaller than testis and uterus was filled with yellowish brown oval eggs.

In a study conducted in crocodile, *Crocodylus porosus* from Northern Australia, a new species of digenean trematode *Renivermis crocodyli* (Blair et al. 1989) was reported. The trematodes were recovered from kidney of this crocodile. The genus *Renivermis* was grouped with the Exotidendriide (Mehera 1935, Simhatrema and Chattopadhyaya 1970). Besides this, *Deurthitrema gingae* in *C. porosus* (Blair 1985), *Deurthitrema* sp. in *C. novaeguinea* (Ladds et al. 1990), *Exotidedndrium* sp. in Nile crocodiles (Foggin 1992) and *Plagiorchid* flukes in *C. novaeguinea* (Ladds et al. 1995) were the important trematodes found in the kidney.

2.1.1.2 Nematodes:

Dujardinascaris helicina (Molin 1860), a robust nematode of brownish colour belonging to the family Ascarididae (Baird 1853) was reported from an American crocodile *Crocodylus acutus* from museum specimens from unknown locality. These were brownish nematodes having cuticle with dense transverse striation. Their lips were shield-shaped with relatively large interlocking process and were provided with anteriorly oriented teeth. Cervical alae were absent. Similarly, *D. waltoni* is another ubiquitous and characteristic parasite of *A. mississippiensis* reported from alligators of South Carolina (Hazen et al. 1878), Florida (Sprent et al. 1977) and Texas (Scott et al. 1997). These nematodes were collected by gastric lavage from live American alligator, *Alligator mississippiensis* in Florida.

A filarial nematode, *Micropluera viviparous* occurring freely in the abdominal cavity was reported by Linstow in 1906 and *Typhlophoros lamellaris* and *Procephalus* were reported to occur in gharials (Ladds 2003). An adult fileroid nematode *Micropleura vazii* (Linstow 1906) and *Micropleura* sp. (Gairhe 2007) belonging to the family Microplueurinae was recovered from abdominal cavity of gharial *Gavialis gangeticus*. Similarly, fileroid nematodes *Oswaldofilaria bacillaris* (Molin 1858) was recovered from the thoracic wall of *Crocodylus crocodilus* and *O. kanbaya* (Manzanell 1906) from *Crocodylus porosus*. The first stage larvae of microfilariae appears in the blood of crocodilian hosts and are ingested by mosquito as an intermediate host and the third stages of larvae are

retransmitted to a crocodilian host by a subsequent bite by the infected mosquitoes (Huchzermeyer 2003).

In study carried out in Ord river area in Western Australia a new nematode species, *Micropluera australiensis* (Moravec et al. 2004) was reported from the peritoneal cavity of the Australian freshwater crocodile, *Crocodylus johnsoni*. A total 30 specimens of *C. johnsoni* were examined. The length of spicule and gubernaculum, the number and arrangement of male caudal papillae, and the postequatorial vulva were its main identifying characteristics. However, no lesions have ever been reported associated with the presence of adult filariae in crocodiles but may invade mosquito optial lobes and ommatids (Prodhon et al. 1972).

The nematode *Crocodilocapillaria longiovata* (Ladds et al. 1990) is an apparently harmless parasite in the stomach of *Crocodylus porosus*, *C. johnsoni* and *C. novaeguinae*. The larvae and adult stages were found in coiled stages in the gastric glands without any apparent tissue reactions (Lads et al. 1995). Similar nematodes were reported by Huchzermeyer in gastric glands of wild-caught *Osteolaemus tetraspis*.

The nematode infection of the ventral scales of the American Crocodile (*Crocodylus acutus*) and Morelet Crocodile (*Crocodylus moreletii*) was studied (Tellez and Paquet-Durand 2011). The study was carried out in Southern Belize during the health assessments performed on crocodiles at the American Education Sanctuary in August 2009. The parasites were responsible for causing imprints on the epidermis and zigzag scars during its movements. The eggs of this parasite were discharged from the skin into the surrounding environment. These were similar to those of cases of capillarioid nematode, *Paratrichosoma* (Ashford et al. 1978) found on the ventral scales of crocodiles in Mexico, Asia and Australia.

Very few numbers of hookworms (Acanthocephala) have been reported in crocodilians. *Polyacanthorhynchus rhopalorhynchus* (Cattoo et al. 1994) in *Crocodylus crocodilus yacarei* in Brazil, *Polymorphus mutabilis* (Groschaft et al. 1970) parasite of fish-eating birds in Cuban crocodiles and third stage larvae of *Gnathostoma procyonis* in muscles of American alligators from Louisiana are the major hookworms reported till now. Fish eating Racoons found in south-eastern USA are the definitive host of the parasite *G. procyonis*, while alligators act as a second intermediary host.

2.1.1.3 Cestodes:

Telford and Campbell in 1981 stated that cestodes are unknown in crocodilians, despite their abundance in most other reptiles but Ladds and Sims in 1990 found a solitary cestode larva and claimed only indication of cestodiasis in crocodiles.

Similarly, larvae (plerocercoids) of the tapeworm *Spirometra erinacei* were detected in the meat of farmed *S. johnsoni* that were slaughtered in the Northern Territory in Australia. These crocodiles were reared in the earth ponds. And a single cestode larva was found deep in the gastric muscularis of a New Guinea or Indo-Pacific crocodile (Ladds et al. 1990).

A cestode larva was reported from a fragment muscle attached to a piece of skin of an African dwarf crocodile during a survey of a wild-caught crocodile slaughtered at markets in Congo Republica in 1996.

However, there is no such published reports of adult tapeworm that are found in crocodiles.

2.1.1.4 Pentastomids:

Pentastomida, tongue worms, are a taxon of 144 species, living exclusively in the respiratory tract vertebrates; amphibians and sauropsids, such as turtles, snakes, lizards, crocodiles, birds, as well as various eutherian mammals such as canids, antelopes, reindeer and marsupials (Spratt 2003). The name pentastomid refers to their five anterior protuberance (five mouth); four of these protuberance are leg-like, and the central one bears the mouth. They have a mixture of annelid and arthropod characters. For that reason, the phylogenetic relationships of the pentastomids have been controversial in proposal of metazoan phylogeny. Human are not the natural host, but can (rarely) become infected as paratenic hosts, resulting in a disease called pentastomiasis or porocephalosis. It is caused by porocephalid taxa *Armillifer* (Sambon 1922), *Lingutuala* (Fröhlich 1789) and *Porocephalus* (Humbold 1809). Direct development in a single host also has been reported (Banaja et al. 1975, Riley 1986).

Fish do not harbor adult pentastomes, but become infected when it ingest infective ova of pentastomes and became intermediate host for piscivorous animals like crocodilians, cheloninans and rarely snakes (Paré 2008). The primary larvae migrate to viscera,

muscles, swim bladder, or other tissues of the infected fish to encyst and develop into nymph. The parasite burden may even kill the fish, especially small species. Fish may also be a source of infection for captive crocodilians (Paré 2008).

Crocodilians are parasitized by six genera of pentastomes; almost all these parasites use fish as an intermediate host (Paré 2008). *Agemas* spp. is found in African dwarf crocodile (*Osteolaemus tetraspis*), slender-snouted crocodiles (*Mecistops cataphractus*); *Alofia* spp. in African and Australian crocodiles, gharials (*Gavialis gangeticus*) in India and Caimens in the Neotropics; *Leiperia* spp. in African and South American crocodiles; *Selfia* spp. saltwater crocodiles in Australia; *Sebekia* spp. in crocodiles all over the world and *Subtriquetra* spp. in caimans and mugger and Indomalayan crocodiles (Junker and Boomker 2006) are the major pentastomes reported from the crocodilians from all over the world.

Pentastomes are more likely to cause clinical disease and pathology in captive reptiles, which may be due to stress. Pentastomid infections are known to impact crocodile and alligator farming operations (Buenbiaje et al. 1994 and Jacobson 2007) because hatchling and young crocodilians appear more susceptible to disease (Adams et al. 2001). The six eggs were collected (Adams et al. 2010) from the nest of a captive African dwarf crocodile (*Osteolaemus tetraspis*) and were incubated. Two hatchlings were died within four hour of hatching from which no parasites were detected and remaining four apparently healthy died without any clinical sign at three weeks of age, one week after being fed live wild-caught fish and commercially raised gold fish; necroscopy revealed presence of multiple white small wormlike organism within lungs, liver and gastrointestinal tract of all dead hatchlings. Histopathological cross sections suggested that pentastomiasis was the major cause of death. The Pentastomid was identified as *S. mississippiensis*.

Out of 23 species of living crocodiles fourteen species have been recorded as being host of one or more pentastomids. The pentastomid parasites of chelonians and crocodilians are currently divided into the family Sebekidae (Sambon 1922) and Subtriquetridae (Sambon 1922). The former comprise seven genera, namely *Agema*, *Alofia*, *Selfia*, *Sebekia*, *Leiperia*, *Diesingia* and *Pelonia*. While the later comprises only one genus *Subtriquetra*.

The genus *Agema* (Riley et al. 1997) is a Pentastomid that inhabit the lungs and bronchioles of the crocodilians host. It includes single species *A. silvaepalustris* (Riley et al. 1997). It is extracted from *Crocodylus cataphractus* and *Osteolaemus tetraspis*. The generic diagnosis: size is small, males claviform, females with uniform diameter and posterior conical ends with blunt point; adult hooks smooth; blades smoothly curved without abrupt right-angled bend near to base; blade on anterior hook pair larger than that of posterior pair; fulcrum without cowl; mouth ovoid and sides of cadre united anteriorly and posteriorly by segments of chitin which appear as two crescents; copulatory spicules delicate and elongate; basal section without a hooked collar (Riley et al. 1997).

The genus *Alofia* (Giglioli 1922) comprises *A. nilotici*, *A. parva*, *A. simpsoni*; (Riley et al. 1995). These pentastomids inhabit the lungs and bronchioles of the crocodilians host. They were all reported from African crocodiles. Similarly, *Alofia ginae* (Giglioli 1922) was reported from crocodiles found in Australasian regions. These all have generic diagnosis: Small: banana shape body; large narrow and curved hooks; U-shaped buccal cadre; caudal extremity of female bluntly rounded, often swollen into a bulb (Riley 1994); simple hooks with minute patches of spines, blades canaliculated, bent through almost a right angle at the base; peg-like extension of oral cadre projects into oesophagus; copulatory spicules with double-hooked collar on the shorter of the two anterior extensions (Riley and Huchzermeyer et al. 1995).

The phylum pentastomida (Huxley 1869); the animal body is divided into a head region with four somites, a trunk with three somites, and a caudal end; full number of somites at hatching; paired uniramous head limbs on head somites three and four developed as attachment devices, three-segmented; first trunk metamere lacking limbs; second and third trunk metameres possessing at most vestigial limbs with a distal tuft of setae and medial pore on proximal segment of limb in the larvae; caudal trunk portion with a pair of outgrowths of papillae (Almeida and Christoffersen 1999; Waloszek and Müller 1994, Waloszek et al. 2006).

The class Eupentastomida (Waloszek, Repetski and Maas 2006) includes recent group of pentastomid with 133 valid species and subspecies; 13 doubtful species. The head appendage one reduced in all stages, modified into dorsal papillae; head appendage two reduced in all stages, modified into frontal papillae; penetrating apparatus consisting of parallel accessory hooks on anterior head margin form larvae to nymphae; proximal

podomere of head appendages 3-4 modified into U-shaped fulcrum from larva to adults; median podomere of appendages in all stages modified into basal plate; trunk in larvae elongate, not segmented; anterior trunk metamere short, close to head; loss of two posterior most trunk segments from somites 6-7; trunk of later larvae and adults made of caudal portion only, which becomes pseudoannulated; cuticular pores all over the body in larvae and adults (Almeida and Christoffersen 1999, Walosezek et al. 2006).

Similarly, the class Eupentastomida is divided into four orders; Cephalobaenida, Raillietiellida, Porocephalida and Reighardiida. The cephalobaenida includes Pentastomid with podial lobes elongate and finger like (Poore and Spratt 2011). In Raillietiellida includes two genus; *Raillietiella* (body tapering at both ends; hooks unequal, posterior pair larger than anterior; three vesicular porjections round each hook) (Brues and Melander 1932, Hett 1934 and Rego 1984) and *Yelirella* (size minute, direct life cycle in respiratory tract of mammal definitive host, glands of cephalothorax and copulatory spicules porocephalid like) (Spratt 2003).

The order porocephalida includes pentastomids with fulcrum campanulate in larvae and boat-shaped in adults; accessory hooks present and dorsal in position from larvae to nymphae; podial lobes absent in adults; hooks disposed in straight line or arc; nervous ganglia fused into single suboesophagic nerve mass in adults; median spine of penetrating apparatus simple in first larval stages; lateral spines of penetrating apparatus bifid in first larval stages; spines of annuli present in nymphae; ejaculatory bulbs present in adults; cirri long in adults; cirrus sac present in adults; copulatory spicule not club-shaped; uterus tubular in adults, greatly elongated and irregularly coiled; female gonopore ventral in adults, posterior, separated from anus by a few rings (heterogyne condition) (Brues and Melander 1932, Self 1969, Almeida and Christoffersen 1999, Poore and Spratt 2011). The order Reighardia include two genus of Pentastomid; the genus *Reighardia* include Pentastomid with loss of terminal papillae/ caudal outgrowths in adults (Almeida and Christoffersen 1999); mature females elongate 7-8 cm and slender, devoid of clear annulations, and the cuticle possesses numerous tubercles with impart a distinctive knobby appearance to the surface (Haffner and Rack 1971 and Dyck 1975).

The class Eupentastomida includes seven family; Cephalobaenidae, Raillietiellidae, Reighardiidae, Linguatulidae, Subtriquetridae, Sebekidae and Porocephalidae. The porocephaloidea consists of two family; Sebekidae and porocephalidae.

In family sebekidae the alimentary canal sinuous, longer than body; hooks distinctly convex, with spines large and prominent; nymphal hooks double; all final hosts are amphibious reptiles (crocodilians, chelonians and monitor lizards, the later including a variety of foods such as carrion, fish, crabs, snails, snakes, terrapins, and eggs of water-birds) (Sambon 1922, Brues and Melander 1932, self 1982, Patterson 1991 and Junker 2002). In porocephalidae, hooks are aligned in adults (Almeida and Christoffersen 1999).

The genus *Sebekia* (Sambon 1922) has some of the general diagnostic features like: Body is short and squat and 58-94 compressed annuli; lateral lines conspicuous; cephalothorax small, wedge-shaped and projecting nipple-like from the abdomen, ventral surface continuous with that of the abdomen; sub-terminal mouth like an inverted 'U' shape; oral cadre oval to elongate, highly variable in shape, without long, parallel sides and generally united anteriorly; hooks small, equal or subequal, claw-shaped, with convex or flat dorsal surface; all hooks spiny (rarely only the anterior pair); all fulcra often with spinous anterior extension (rarely only the anterior pair); hook barb curved, strongly united and continuous with shank; spicules generally obpyriform, with one or two fine sclerotized rods supporting rods supporting membranous region distally. Parasites of the lungs of crocodilians, rarely of chelonians (Riley et al. 1990).

Leiperia cincinnalis (Sambon 1922) from Nile crocodiles, *Crocodylus niloticus* from Kruger National park of South Africa; claviform male and banana shape female of *Agema* (Riley et al. 2000), a monotypic pentastomid from wild-caught and market-derived crocodiles, *Osteolaemus tetraspis* and one slender-snouted crocodile *Crocodylus cataphractus* are the major pentastomids reported from trachea and lungs of the crocodilian host.

A study on pentastomid *Sebekia oxycephala* (Venard et al. 1941) was carried out in the fishes of Florida. For this they collected the fishes from different channels of the streams. Thirty-one parasites were collected from the surface of liver under the peritoneum and in the mesenteries. Within the cyst the parasite assumes a characteristic shape; entire body was ventrally flexed and the abdominal portion is coiled underneath the head. They possessed segments from 64 to 68. The head was with four hooks and with a conspicuous mouth. The stigmata were found on all segments and the head. The stigmata do not occur in definite rows (Holl 1928 and Heymons 1935).

2.1.2 Nepalese context:

Although, many study on the ecology and habitat of gharial has been conducted in Nepal only a single study on parasitology has been conducted which focuses much more need of attention. A single nematode *Micropleura* sp. belonging to the family: Micropleuridae was reported (Gairhe 2007) in the body cavity of the death gharial hatchlings. Similarly, two digenetic trematodes; *Pseudoneodiplostomum* sp. and *Proctocaecum* sp. were also reported from the different region of alimentary canal of captive gharial hatchlings at the Chitwan National Park, Nepal. This is only a report available till date regarding the helminthic infections in Gharials of Nepal.

In that study the digenetic trematode, *Proctocaecum gairhei* (Junker K. and Brooks D.R. 2008) belonging to the family Cryptogonimidae (Ward 1917) was identified which was the species of trematodes from gharials of Nepal. The parasites were obtained with the prevalence of 5.84% from the small intestine. Body of this parasite was elongated, slender and slightly tapering towards posterior end. The tegument was without spines and contains two suckers; oral sucker was funnel-shaped with uninterrupted row of 23 spines. The parasites were responsible for enlargement and shortening of the duodenum and the gross thickening of the mucosa at the opening of the bile duct into the duodenum but he couldn't directly relate with the mortality of gharial hatchlings.

The digenetic trematode, *Exotidendrium* sp. were reported (Gairhe 2007) from the gharials of Nepal with the prevalence of 40.95%. Both mature and immature forms were isolated in a range of 100-300 in the colo-rectal lumen and around the sphincter orifice. Their body were elongated (1.5 ± 0.25), slender anteriorly and swollen at the posterior part much like that of Nepalese earthen pot for keeping the water cool. So, due to its shape it was named "Surahi fluke". The parasites were responsible for a pathological condition called "Sphincter Cap" and according to that study it was characterized by a distinct whitish, blackish, yellowish, yellowish green or greenish granulomatous scab around the colorectal orifice with bacterial infections.

3. MATERIALS AND METHODS

3.1 Study area:

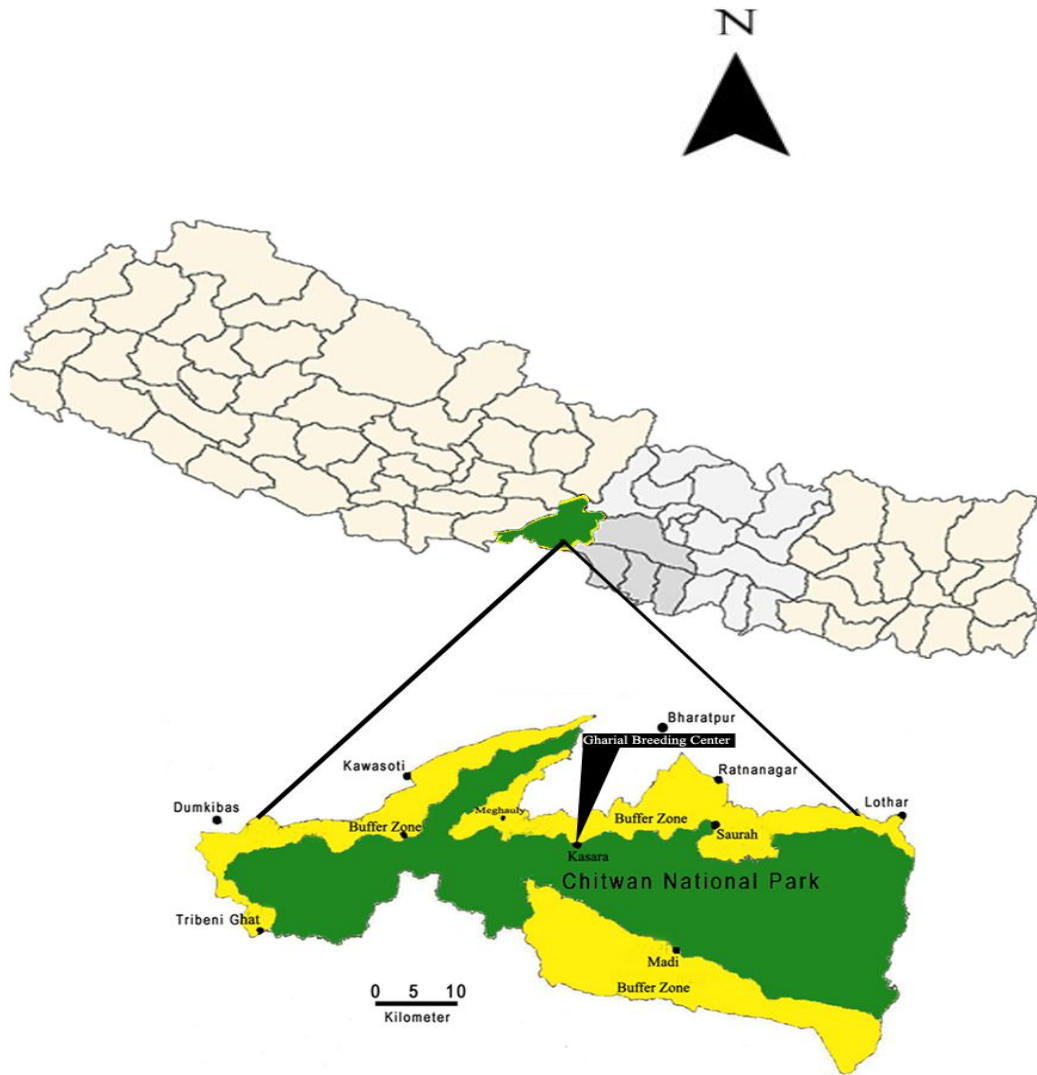


Figure1. Study Area

Nepal is the one of the most prosperous country in the world owing diversity of flora and fauna, unique geographical composition and diverse climate where one can get every things in few steps of exploration. It is one of the landlocked country in the world with lots of fast flowing rivers that have potential to irrigate the entire land and to produce hydropower that can enlightens other country too. Geographically, it is 80^o 4" to 88 12" East longitude and 26^o 22" to 30^o 27" North latitude. It is approximately 885 km in length and its mean width is 193 km with a total land area of 1,47,181 square kilometers.

The study area is Kasara, Royal Chitwan National Park which is one of the most panoramic and wealthy place of biological treasure and first step of every nature lover and first initiation for different biological scholars. It is located between 27 20'32"-27 41'23" North latitudes and 83 52'40"-84 44'34" East longitudes and its buffer zone is located between 27 16'56"-27 42'13" North latitudes and 83 50'23"-84 46'25" East longitudes in the south-central lowland Nepal (RCNP 2002). The first declared National Park under the National Parks and Wildlife Conservation Act 1973, later it was listed as World Heritage site in 1984 (RCNP 2004) as recognition to its unique and internationally significant pristine ecosystem (Mishra et al. 1991). The park is bounded by Narayani River in the southwest, East Rapti River in the north and Reu River in the South. The park receives mean annual rainfall of about 2150 (nearly 80 percent of annual precipitation that occurs during the monsoon period). In June temperature rises up to 43 with frequent rain and humidity. The water temperature of the Narayani River reaches as high as 34^oC during the month of August and lowest 13^oC during January (Maskey 1989). Incidence of flooding is very common in the river systems during monsoon.

3.2 Materials used:

The study was carried out in the veterinary lab of buffer zone. The materials that were used during the course of study have been listed below:

3.2.1 Laboratory tools:

- | | | |
|------------------------------|-------------------|----------------------|
| i. Plastic bags | ii. Gloves | iii. Dissecting tray |
| iv. Digital weighing machine | v. Measuring tape | vi. Leucoplast |
| vii. Scissors | viii. Forceps | ix. Needle |
| x. Blade | xi. Petridish | xii. Watch glass |
| xiii. Slides | xiv. Cover slip | xv. Tea stainer |

xvi. Centrifuging machine

xvii. Microscope

xviii. Rubber band

xix. Beaker

xx. Test tube

xxi. Vials

3.2.2 Chemicals used:

i. Alcohol series

ii. DPX mount

iii. 10% formalin

iv. Xylene

v. AFA solution

vi. Lacto phenol

vii. Nail polish

viii. Glycerine

ix. Gower's stain

x. Zinc Sulphate

3.3 Sample collections:

The Gharial hatchlings after their death were collected from GBC, Kasara (Batch 2011-12) every morning. These dead hatchlings were then transported to the Veterinary laboratory camped at Sauraha, Chitwan National Park in a plastic bag, labeled with date of collection and were again stored in the refrigerator in a frozen conditions until its internal organ were exposed.

3.4 Dissection and lab works:

Before dissection, the dead hatchlings were washed carefully in the plastic tray and all the dirt and sand particles were removed. Then the bodies were weighed by using digital weighing machine and length was measured from the tip of snout to the tip of tail using measuring tape. The dead hatchlings were inspected if there were any external injuries or infections.

The dead hatchlings were dissected in ventro-dorsal position. The skin was incised starting from caudal at the level of hind limb up to the base of neck region (Huchzermeyer 2003). Then the abdominal cavity were exposed and various visceral organs were slowly pulled outside the body and they were cut and were kept at different petridish containing normal saline for microscopic examinations.

PLATE I



Photo 1

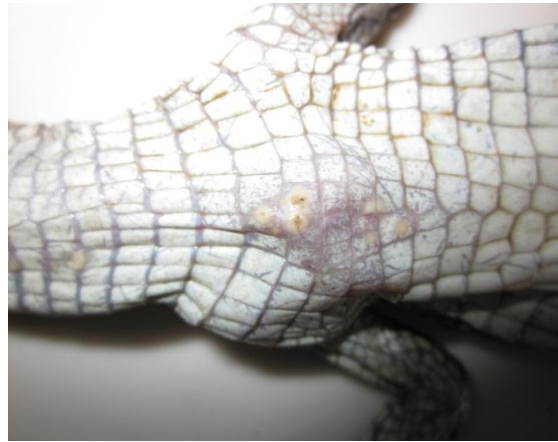

Photo 2



Photo 3



Photo 4

Photo 1: Inspecting ventral surface of the dead gharial hatchling. Photo 2: Parasitic infection nearby neck region. Photo 3: Measuring the body length. Photo 4: Dissecting the dead gharial hatchling.

PLATE II

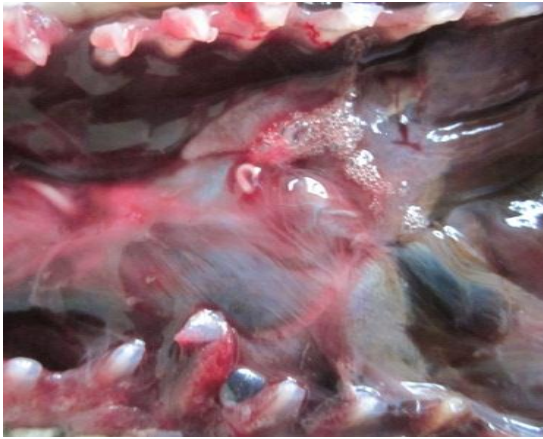

Photo 5

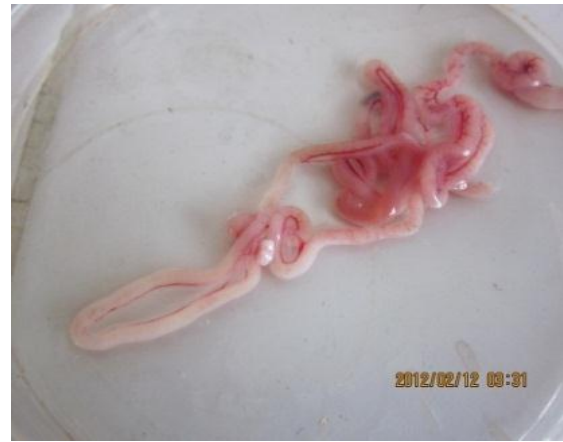

Photo 6

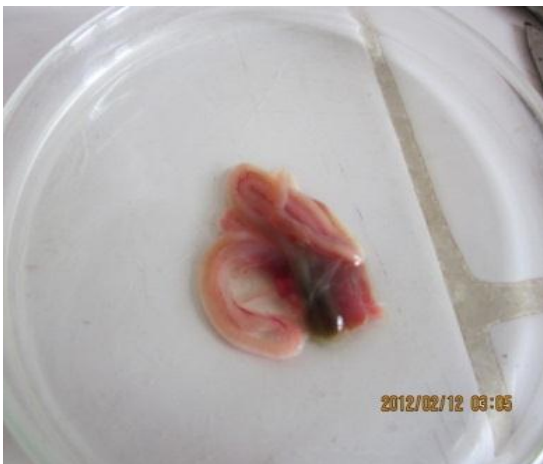

Photo7

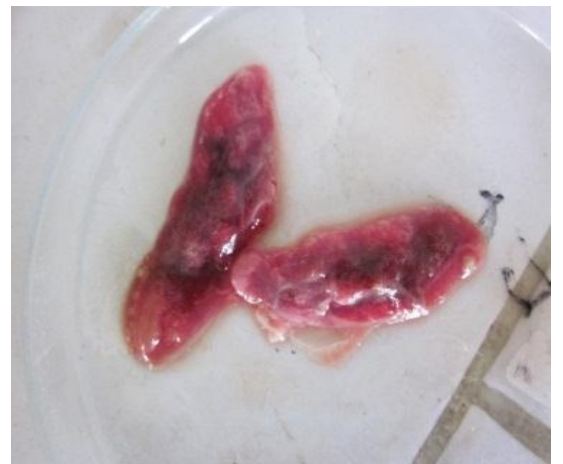

Photo 8

Photo 5: Pentastomid larva in mesentery. Photo 6: Small intestine with nodes. Photo 7: Small intestine for inspection. Photo 8: Lungs for inspection.

PLATE III

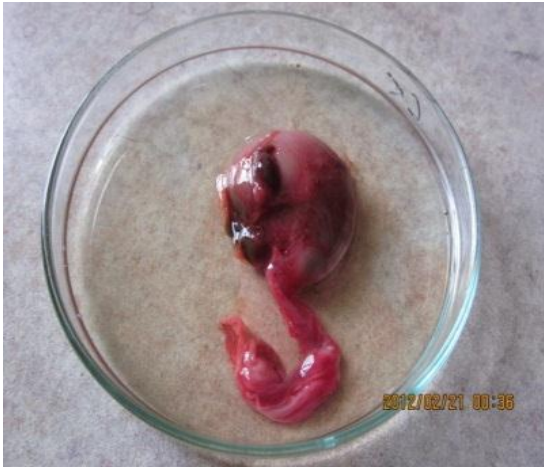

Photo 9

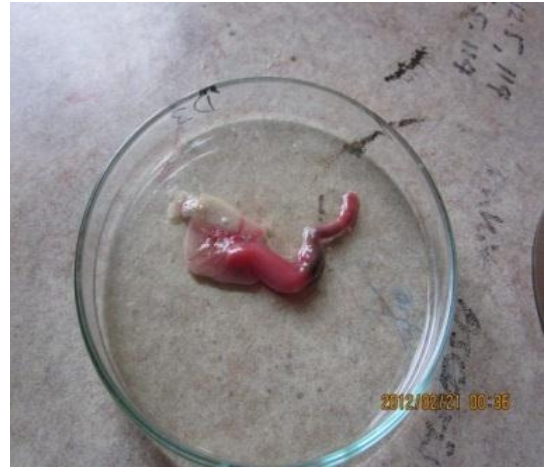

Photo 10

Photo 9: Stomach for inspection. Photo 10: Rectal region for inspection.

3.4.1 Extraction of helminthes, their preservation and slide preparation:

After the detection of the helminth parasites, they were collected in the normal saline and were preserved in 70% ethanol and were proceeded for the permanent slide preparation for further identification.

3.4.2 For nematode parasites:

Preserved nematode parasites were kept in lacto phenol for half an hour for clearing the internal organs of the parasites and were mount in glycerine for further identification of the parasites. The glycerine mount was sealed with nail polish.

3.4.3 For trematode parasites: Adult trematodes and cestodes parasites were collected and washed in normal saline water. The parasites were pressed in between two slides or with large coverslip depending upon the size and fragility of the parasites. The pressed parasites were fixed and preserved in the AFA solution for 24 hours. Fixed parasites in AFA were gently removed and washed for three times in distilled water and were proceeded for alcohol dehydration process. Alcohol series of 30%, 50%, 70%, 90% and absolute were prepared and parasite samples were dehydrated for required time depending upon the size and nature of the parasite sample. After 70% series the samples were stained with Gower's satin and after absolute alcohol the samples were checked for complete dehydration Xylene solution. When there was white precipitate with xylene solution, it was confirmed that the dehydration was incomplete and re-hydration process was done; going back to 70% ethanol was followed. If not they were prepared for permanent mount.

3.4.4 For pentastomid parasites: The pentastomids were collected in the normal saline and then preserved in the 70% ethanol until they were proceeded for slide preparations. Both temporary slide and permanent slide preparation was done. For temporary slide preparation the pentastomids were kept in lactophenol for 5 minutes and was mounted over glycerine for study. Similarly, for permanent slide preparation same procedures were applied as that for trematodes.

3.4.5 Egg of parasites: The intestinal contents of the Gharials were collected in sterile vials separately from different region of the intestine. The intestinal contents were examined by using both fecal floatation as well as sedimentation methods for the isolation and identification of the parasitic eggs. The samples were examined using normal saline

solutions as well as iodine stain. The observed parasitic eggs were measured using oculomicrometer and were photographed.

3.6 Identification

The pentastomid was identified to its family level with the help of its check-lists found in different hosts and with the taxonomic keys mentioned in "A systematic monograph of the Recent Pentasomida, with a compilation of their hosts", by M.L. Christoffersen and J.E. De Assis published in 2013. Similarly, trematode and nematode was identified by comparative studies of previous findings and published articles. While the eggs were identified by the help of available references of microphotographs.

3.7 Data analysis

Since, the study was mainly focused in the isolation and identification of gastrointestinal helminth parasites of captive gharial hatchlings the data were analysed using Microsoft Excel 2010. Similarly, the comparative studies were also done by representing various data in suitable pie-diagrams and tables.

4. RESULTS

4.1 First report of pentastomid *Sebekia* sp. in gharial (*Gavialis gangeticus*) from Nepal:

DESCRIPTION OF SEBEKIDAE:

a. Phylum: Pentastomida (Huxley 1869)

The parasite bodies were divided into two distinct regions; cephalothorax and trunk. The cephalothorax bears two pairs of hooks (Photo 11); mouth in ventral position (Photo 13); trunk is provided with distinct annuli (Photo 12); minute pores were distributed in each annulus (Photo 12); pores were also distributed in cephalothorax region (Photo 13); the caudal end tapers into rounded blunt point (Almeida and Christoffersen 1999, Junker 2002).

b. Class: Eupentastomid (Waloszek, Repetski and Maas 2006)

Head appendages are reduced in all stages and modified into papillae; penetrating apparatus consists parallel accessory hooks on anterior head margin from larvae to nymphae; proximal head appendages were modified into fulcrum from larva to adults; adults body were pseudoannulated; the cuticular pores were distributed all over the body in larvae and adults (Photo 12 and 13) (Almeida and Christofesen 1999, Waloszek et al. 2006).

c. Order: Porocephalida (Heymons 1935)

Due to the presence of finger like podial lobes (Poore and Spratt 2011), the observed pentastomid does not belong to first order Cephalobaenida. Similarly, the characters of two genus (*Reighardia* and *Hispani*) belonging to the second order Reighardiida were compared. The genus *Reighardia* could not be confirmed as it is without clear annulations, and the cuticle possesses numerous tubercles which impart knobby appearance to the surface (Haffner and Rack 1971, Dyck 1975). The second genus *Hispania* also does not confirmed as it does not possess such distinct annulations and wedge shaped cephalothorax regions. So, final confirmation to the order Porocephalida was done on the basis of presence of boat-shaped fulcrum, absence of podial lobes,

hooks disposed in straight line or arc (Photo 11) and spines of annuli that are present in nymphae (Photo 12 and 14) (Almeida and Christoffersen 1999, Poore and Spratt 2011).

d. Super family: Porocephaloidea (Sambon 1922)

The superfamily Liguatuloidea could not be confirmed as its body are flattened (fluke like) (Melander and Brues 1932, Riley 1986). Similarly, this superfamily was confirmed due to the presence of hooks with fulcrum (Photo 15) (Rego 1984, Almeida and Christoffersen 1999).

e. Family: Sebekidae (Sambon 1922)

Since, the hooks were aligned in adults (Almeida and Christoffersen 1999) it could not be confirmed as the family porocephalidae and were grouped under this family Sebekidae. This possess the important characters like distinctly convex hooks (Photo 16), double nymphal hooks (Photo 11 and 15) and all the final host are amphibious reptiles (crocodilians, chelonians and monitor lizards) (Sambon 1922, Brues and Melander 1932, Self 1982, Patterson 1991 and Junker 2002).

f. Genus: *Sebekia* (Sambon 1922)

The family sebekidae includes eight genus; *Leiperia*, *Sambonia*, *Selfia*, *Alofia*, *Diesingia*, *Agema*, *Sebekia* and *Pelonia*. The genus *Leiperia* has V-shaped oral cadre (Riley & Huchzermeyer, 1996, Junker et al. 2000) as this pentastomid bears inverted 'U' shaped oral cadre (Photo 11 and 13). The adult *Samobonia* parasitize monitor lizards and also parasitizes crocodilians. Similarly, *Selfia* spp., *Alofia* spp. and *Diesingia* spp. bears single row of chloride cell pores per annuli (Junker 2002) but this pentastomid bears the irregular patches of chloride cell pores per annuli (Photo 12) so the characteristics of these genus does not resembles. Due to ovoid mouth of *Agema* (Riley et al. 1997), the characteristic does not resemble to each other. Similarly, *Pelonia* parasitize the lungs of final host i.e. Chelonians (Junker and Boomker 2002, Riley and Boomker 2003).

Similarly, *Sebekia oxycephala* (pentastomida) (Venard et al. 1941) bears irregular chloride cell pores in each annulus. So finally, the observed Pentastomid in the body cavity (Riley and Huchzermeyer 1851) can be confirmed to the genus *Sebekia*.

PLATE IV

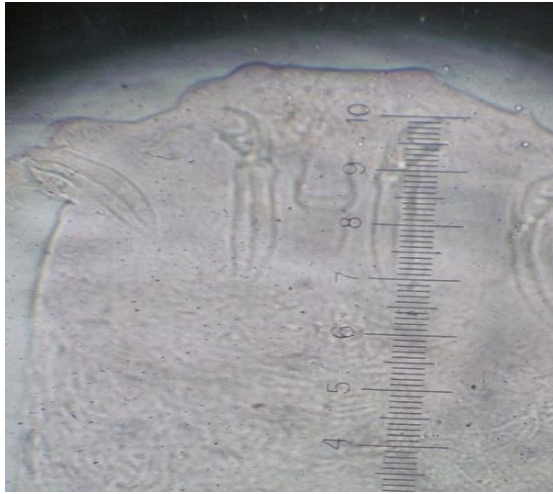


Photo 11(10X x 10X)




Photo 12(10X x 40X)

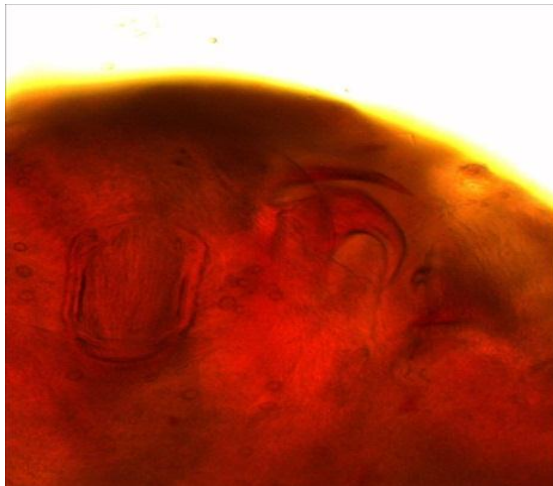


Photo 13(10X x 40X)

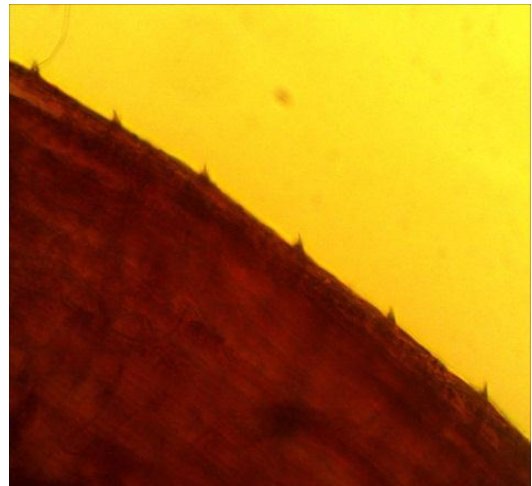


Photo 14(10X x 40X)

Photo 11: Pentastomid nymphs with two pairs of ventral and subterminal mouth. Photo 12: The trunk annuli with irregular chloride cell pores in each annuli and its margin fringed by a prominent row of backwardly directed spines. Photo 13: A portion of cephalothorax showing the inverted "U" shaped subterminal oral cadre. Photo 14: The lateral view of trunk showing backwardly directed spines.

PLATE V



Photo 15(Cropped portion of anterior part)

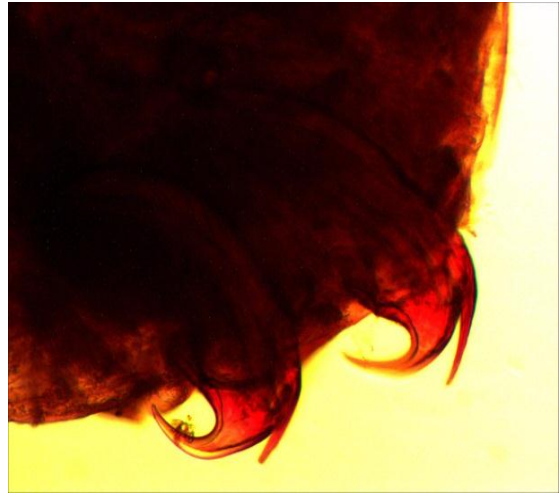


Photo 16(10X x 40X)



Photo 17(10X x 20X)

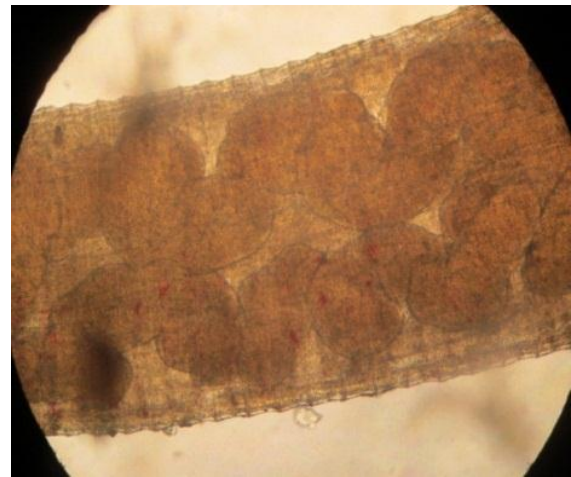


Photo 18(10X x 20X)

Photo 15: A whole structure of hook with fulcrum at its base and double hook at its tip; anterior and posterior hooks. Photo 16: Lateral view of hooks showing its convex surface. Photo 17: Lateral view of anterior portion of pentastomid with internal structure. Photo 18: Middle portion of pentastomid showing internal structure.

PLATE VI

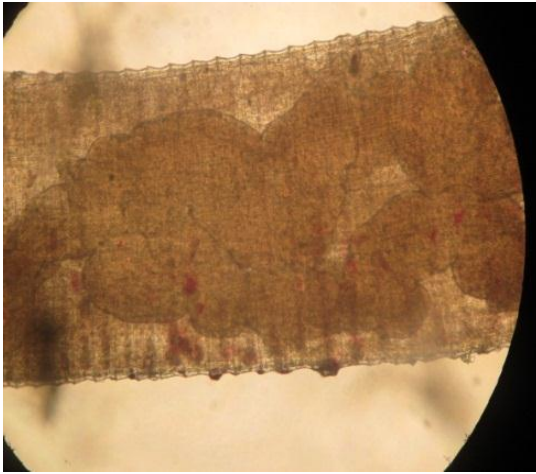


Photo 19(10X x 20X)



Photo 20(10X x 20X)

Photo 19: Internal organ nearby posterior end. Photo 20: Internal organ at the posterior end.

Table 1: The characteristics of the Pentastomid (Family: Sebekidae) in this paper.

Species	Length	Width	No. of annuli	Hook dimensions		Fulcrum length	Mouth dimensions		
				Overall length	Blade length		Overall length	Cadre length	Cadre width
<i>Sebekia</i> spp.	6-7mm	1mm	75-90	103.3 µm	51.65 µm	237µm	144.62 µm	134.29 µm	82.64 µm

Table 2: The principal characteristics of the Pentastomid (Family: Sebekidae) from *Osteolaemus tetraspis* examined in the study (J. Riley and F.W. Huchzermeyer 1995).

Species	Sex	Length	Width	No. of annuli	Hook dimensions		Fulcrum length	Mouth dimensions		
					Overall length	Blade length		Overall length	Cadre length	Cadre width
<i>Sebekia okavangoensis</i>	F	18-23	1,3	93/4	105±24	48,5±24	284±24	450	320	210
	M	14	1,1	87(?)	86	40	240	-	240	175
<i>Sebekia</i> Spp.	F	10	2,2	56	60	38	160±3	345 355	250 250	117 115
"Preadult"	F	6,4	0,95	-	64	33	150	-	210	120
Smooth-hooked nymphs	?	4,1-6,8(5,5)	0,6-1,1(0,9)	-	47±4	-	140*-170	256±20	174±1 5	94±1 1
Double hooked nymphs	?	3,5-7,3(5,5)	0,6-1,0(0,8)	56-61	81.5±6. 3	-	165±22	202±17	133±1 1	88±1 0
<i>Alofia parva</i> n. sp.	F	5,3-7,5(6,4)	0,8-1,3(1,0)	65(?)	79±4,2	41±3,5	180±16, 5	307±18	240±1 3,5	97,5± 6,0
	M	4,3-5,0(4,5)	0,5-0,7(0,5)	59(?)	-	37,5±3, 6	156±13, 5	234±13	185±1 2	74±4, 3

4.2 First report of Nematode parasites in gharial (*Gavialis gangeticus*) from Nepal:

4.2.1 Description of capillarioids (family: Capillariidae):

These are the medium-sized filiform nematodes; anterior end of body is narrow, rounded and indistinct cephalic papillae. The two lateral bacillary bands is distinct, fairly wide extends almost to whole body length. Oesophagus is muscular and relatively short. The stichosome consisting of single row of about 38-40 stichocyte is subdivided usually (mainly in posterior part of stichosome) into 10-15 transverse annuli; nuclei of stichocyte is large. The nerve ring encircles the muscular oesophagus at its first third part. Two wing-like cells are present at oesophago-intestinal junction.

The female body is shorter and broader than male. In male, stichocytes are less in number in comparison to the female nematode. Seminal vesicle is oval, short and spicule is well sclerotized; proximal end of spicule is simple, non-expanded, slightly dorsally curved and distal is rounded. Spicular canal is not developed. The surface of spicular sheath is smooth, with or without spines. Bursa is supported by two wide lateral lobes reaching posteriorly almost to posterior border of bursa. Lateral caudal alae may be present or absent. Similarly, in female vulva is situated at the posterior to the level of oesophago-intestinal junction; vulval lips are not elevated. Eggs are arranged in single file in uterus. Eggs are barrel shaped and are with or without distinctly polar plugs (Photo 23)

4.2.1.1 Keys to genera *Crocodylocapillaria helicina*:

This is one of the most important capillarioids, that are found to use crocodilians host namely *C. porosus*, *C. johnsoni* and *C. novaeguineae* (Ladds et al. 1995). The nematode lives in the stomach of crocodiles and lay one of the most diagnostic; unusually long eggs (hence their specific name) with distinct polar poles (Photo 23), which is eventually become embryonated.

4.2.2 Description of Nematoda (Family: Ascarididae, Baird 1853):

This family includes large number of ascaridoid species that have been reported from many crocodilians. Among these species nematodes such as *Dujardinascaris woodlandi* (Sprent 1977), *Goezia gavialidis* (Sprent 1978), *Multicaecum agile* (Graber 1981) and *Typhlophorus lamellaris* (Sprent 1983) were reported from *Gavialis gangeticus*.

One of the important nematode, *Dujardinascaris helicina* (Syn. *Ascaris helicina* Molin 1860). This species was originally described by Molin in 1860 as *Ascaris helicina* from an American crocodile *Crocodylus acutus* and later on this species was reported from different crocodiles from Africa and Asia (Sprent et al. 1977).

It is the robust nematode of brownish colour. The cuticle possesses dense transverse striations. Anterior portion possesses shield-shaped lips with relatively large interlocking processes. Middle anterior region of lips are semicircular; provided with row of prominent and anteriorly oriented teeth. The surface of pulp is located just posterior to teeth forming four distinct lobes. Interlabia is well developed having triangular shape and reaches anteriorly mid-length of lips. The cervical alae are absent. Oesophagus is almost spherical and a long anterior dorsal intestinal caecum is present. Nerve ring encircle the oesophagus approximately at 1/5-1/6 of its length. Excretory pore is approximately at the level of nerve ring and deirids are present at short distance posterior to it.

The male measures about 14.185 mm in length and 0.571 mm in width. Deirids are not located. It contains anal papilla; preanal papillae consists 5 subventral pairs and last 2 pairs just anterior to cloaca. Similarly, adanal papillae consists 1 lateral pair of large papillae and post anal papillae consists 3 pair of subventral, 2 dorsolateral and a lateral pair of minute papilla like phasmids between last subventral and last dorsolateral pairs of postanal papillae. The proximal end of gubernaculum is expanded to form marked dorsal lobe, while the distal end is pointed. Tail is conical with sharply pointed tip.

Similarly, the female measures about 19.17 mm in length and 0.93 mm in width. Vagina is directed posteriorly. Eggs are almost spherical, thin-walled with smooth surface; size 0.075-0.083 x 0.063-0.075 mm and thickness of wall 0.002-0.003 mm. Contents of eggs are mostly uncleaved or cleaved at most into four blastomeres. Tail is conical with sharply pointed tip and pair of distinct papilla-like outlets of phasmids are present approximately at mid-length of tail.

4.2.2.1 Keys to genera *Dujardinascaris helicina*:

This intestinal parasites is characterized by the presence of well-developed lateral alae and the absence of teeth on lips (Groschaft et al. 1970).

Mostly the site of infection is stomach but during this research the almost circular (Photo 22) egg of *Ascaris* was reported from small intestine. The details of this nematode cannot be explained, as its major anterior portion was cut (Photo 21) during the exposing of small intestine and parts were not found. Simply, the genus was confirmed by the detection of egg from small intestine of the same infected hatchling and its measurements are given in the table 3.

PLATE VII

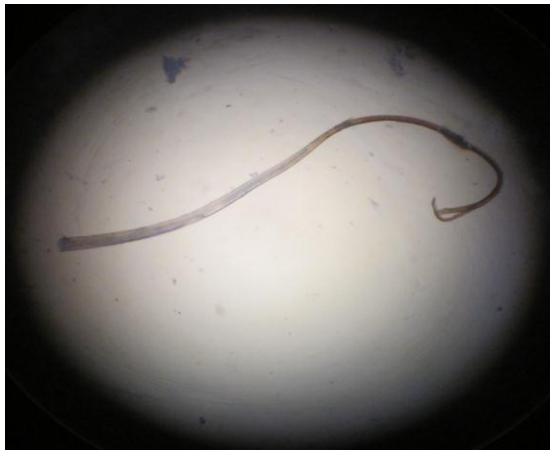

Photo 21(10X x 10X)

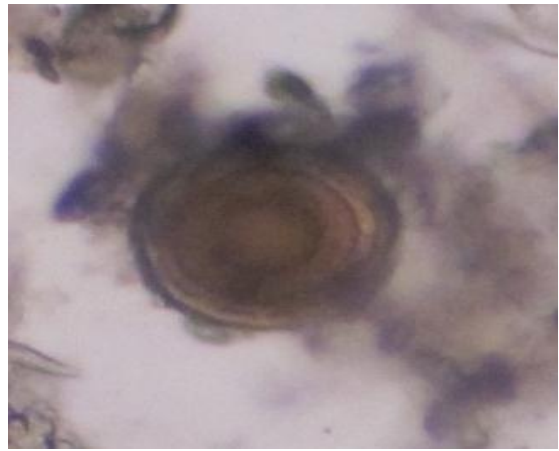


Photo 22(10X x 10X)

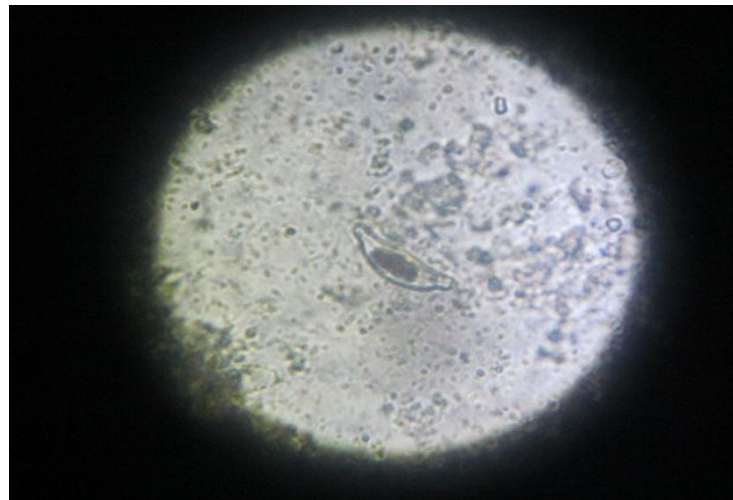


Photo 23(10X x 10X)

Photo 21: A cut portion of adult ascaridoid. Photo 22: Egg of ascaridoid. Photo: 23
Capillarioid egg with elongated polar poles.

Table 3. Measurements of various parts of Ascaridoid egg.

Title	Measurements (μm)
Total diameter	65
Cell wall	10.33
Embryonic layer	41.32
Innermost embryo	20.8

4.3 Trematode parasites of gharial (*Gavialis gangeticus*):

4.3.1 Description of *Proctocaecum gairhei*.

Type-locality: Gharial Breeding Centre of the Chitwan National Park, Kasara, Chitwan, Nepal

Site of extraction: Small intestine

Prevalence: 3.52%

Classifications

Phylum: Platyhelminthes

Class: Trematoda

Order: Digenea

Family: Cryptogonimidae (Ward 1997)

Genus: *Proctocaecum* (Baugh 1957)

Species: *gairhei* (Junker et al. 2008)

4.3.1.1 General characteristics of family: Cryptogonimidae:

The body of this trematode is very elongated (Photo 24) with rounded or slightly attenuated extremities. The cuticle is armed with spines from anterior end to the level in front of ovary; the spines are thickly set anteriorly and are sparse posteriorly. Oral sucker is well developed and is funnel shaped in terminal part (Photo 25 and 26). The oral sucker is provided with 21 or 25 to 26 cephalic spines (Photo 26) arranged in a single row. Acetabulum is very much anterior in position, only a short distance behind oral sucker. Pharynx is separated from oral sucker; oesophagus is very short or practically absent. The intestinal caeca is long, narrow and reaches upto the posterior end of the body.

Testes are tandem, oval, postovarial and are located near the posterior end of the body. Seminal vesicle is long, free in parenchyma and is located in transverse coils between uterine coils or vitelline glands and acetabulum. The common genital pore is median, immediately preacetabular and leads into a moderately developed sinus.

Ovary is oval in shape; immediately pretesticular and it is located to one side of median line. Receptaculum seminis is prominent and lies between ovary and first testis; Laurer's canal is present. Shell gland is diffuse. Uterus is long, coiled and confined between intestinal caeca and extends from in front of ovary to acetabulum. Vitellaria are in the form of small follicles; occupies lateral sides of the body from near junction of anterior and middle third of the body length to a short distance in front of level of ovary. Eggs are numerous (Photo 32), thick shelled, yellowish, operculated (Photo 33) and are with miracidia. Excretory bladder roomy; opens exteriorly through a post terminal excretory pore.

4.3.1.2 Keys to genera of Cryptogonimidae:

The digenetic trematode, *Proctocaecum gairhei* can be differentiated from other species of *Proctocaecum* (Baugh 1957) by the considerations of some of the following important morphological characteristics: presence of solid muscular gonostyle (Photo 30) and single row of 23 cephalic spines (Photo 26), lateral position of anal pores that opens at uneven levels, forebody occupies 16% of the total body length, an oral to ventral sucker width ratio of 1:0.7, an oral sucker to pharynx width ratio of 1:0.6 and uterine loops occupies 59-67% of total body length.

From this comparative study, most of the measurements resemble with each other and only a few differences occur in different parts of parasites. The number of cephalic spines accurately matches and so we can confirm this trematode is the *P. gairhei*.

PLATE VIII

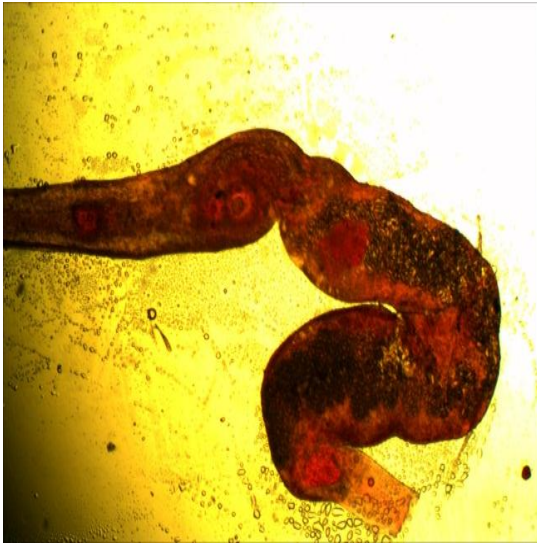


Photo 24(10X x 4X)

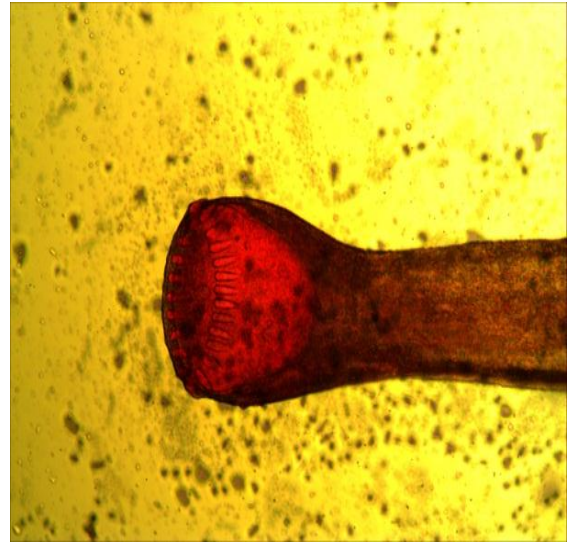


Photo 25(10X x 10X)

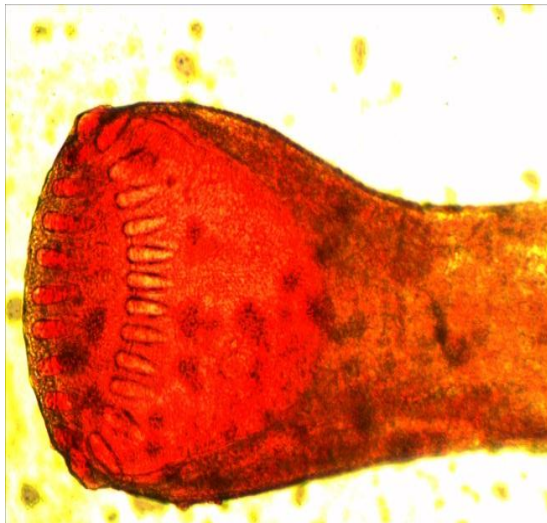


Photo 26(10X x 20X)




Photo 27(10X x 40X)

Photo 24: Elongated body of *P. gairhei* without any cuticular spines. Photo 25: Funnel shaped anterior sucker with oral spines. Photo 26: Oral sucker with 23 spines. Photo 27: Unstained portion of oral sucker with spines.

PLATE IX

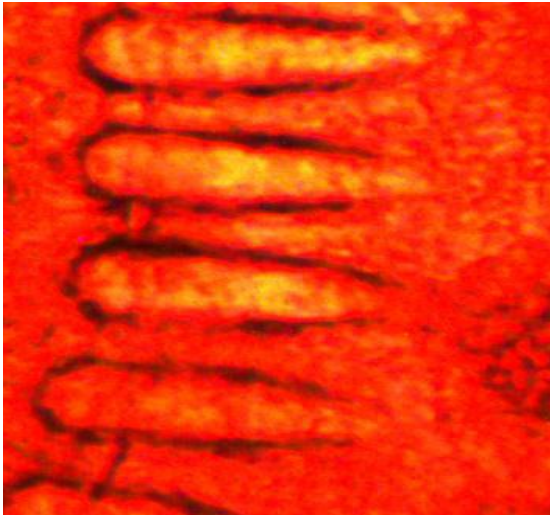

Photo 28(10X x 40X)

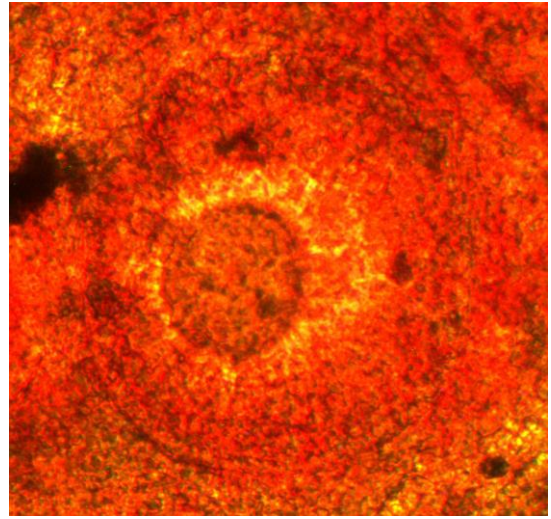


Photo 29(10X x 40X)

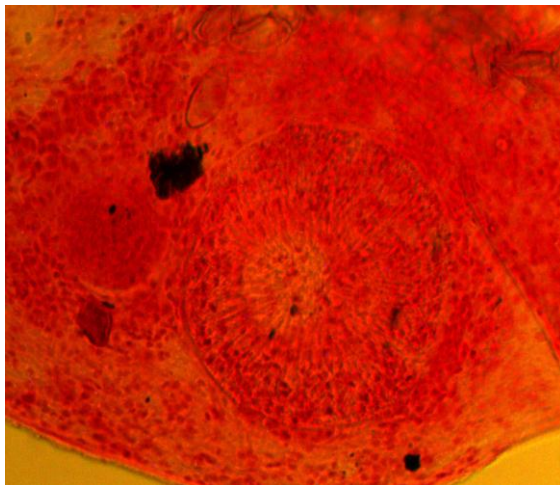


Photo 30(10X x 40X)

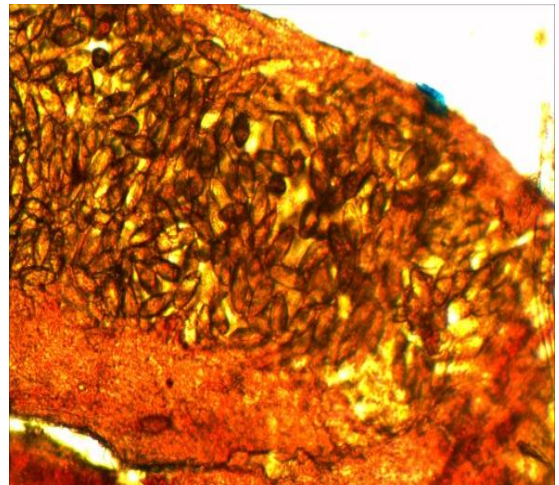


Photo 31(10X x 20X)

Photo 28: Oral spines with rounded anterior end and pointed posterior end. Photo 29: An enlarged view of ventral sucker. Photo 30: A muscular gonotyle just anterior to the ventral sucker. Photo 31: A body portion filled with large number of eggs.

PLATE X

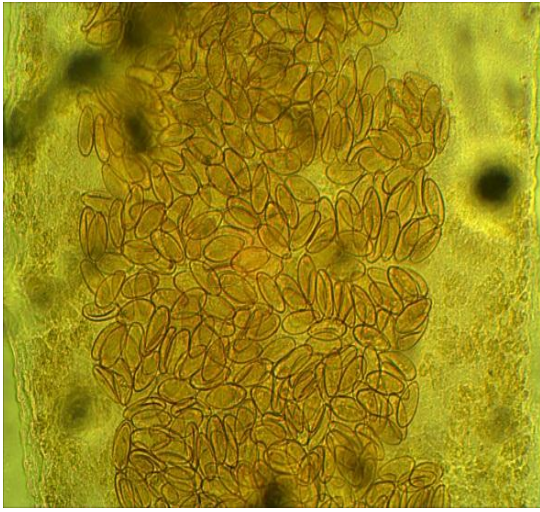


Photo 32(10X x 10X)

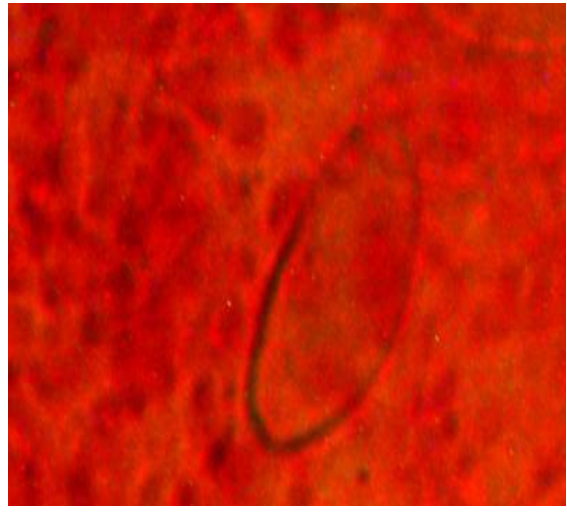


Photo 33(10X x 40X)

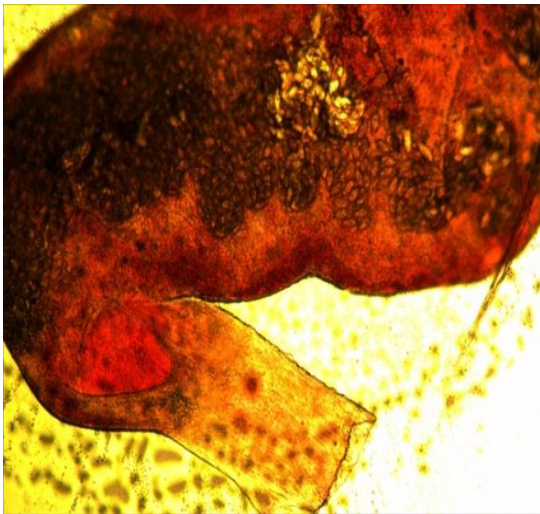


Photo 34(10X x 10X)

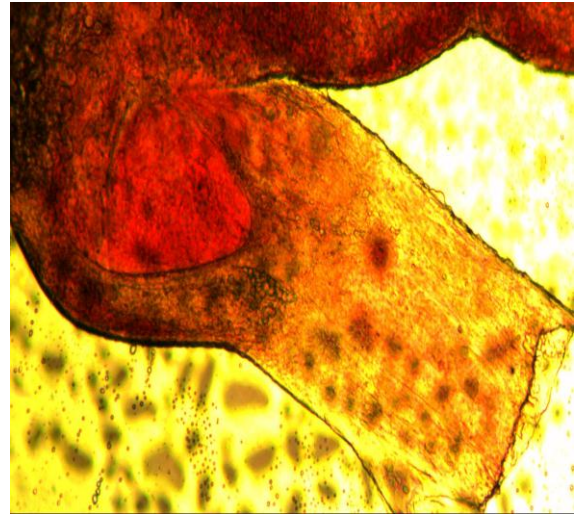


Photo 35(10X x 20X)

Photo 32: An enlarged portion with clusters of operculated eggs. Photo 33: A single magnified egg showing the operculum at one end. Photo 34: Posterior part of *P. gairhei*. Photo 35: An enlarged portion of posterior end of *P. gairhei*.

Table 4: Comparative measurements of *P. gairhei* (Junker et al. 2008).

Title	In this paper	Average measurement (Junker et al. 2008)
Body length	3750	3749
Body width at the ventral sucker	376.3	376
Body width	10.2	10
Oral sucker length	291.3	291
Oral sucker width	300.2	300
Ventral sucker length	172.11	173
Ventral sucker width	210	212
Gonotyl length	46.12	47
Gonotyl width	73	72
Fore body	629	627
Egg length	29	37
Egg width	16.32	17
Number of cephalic spines	23	23
Width of cephalic spines	43.4	43

4.3.2 Description of *Exotidendrium* sp.:

Classification:

Phylum: Platyhelminthes

Class: Trematoda (Rudolphi 1808)

Order: Fascioalatoidea (Szidat 1936)

Family: Exotidendriidae (Mehera 1935 Status emended)

Genus: *Exotidendrium* sp.

The trematode of this genus, *Exotidendrium gharialii* (Mehera 1935) were obtained in large numbers from the rectum near the cloaca of gharial *Gavialis gangeticus* (Gmelin 1789) at Allahabad, India. Similarly, it was also reported from Nepal (Gairhe 2007) in cloacal region of gharial hatchlings at GBC, Kasara, CNP, Nepal and showed the significance relationship between lesions "Sphincter cap" at cloacal region and the parasites of this genus. The same genus in this research was also reported from cloacal region of the same host and in the same site.

4.3.2.1 General diagnosis of family Exotidendriidae:

The body of this trematode is minute, elongated; anterior end slender and posterior end swollen (Photo 36), covered with spines (Photo 38) and provided with two feebly muscular suckers in the ratio 2:3; larger ventral sucker is a little pre-equatorial (Photo 39) in position. Prepharynx and pharynx are present. The long oesophagus leads to somewhat saccular and extremely short intestinal caeca; not extending behind the ventral sucker. The gland cells are distributed entirely around the gut.

The genital pore is post-bifurcal and varies in position with respect to the acetabulum. The testes are nearly parallel (Photo 39), often oblique to tandem, pre-ovarian, behind acetabulum and are located at the middle of the body length. The large S-shaped cirrus sac extends a little in front of the hinder part of the body. The vesicula seminalis is straight, ovoid and present inside the cirrus sac. The pars prostatica is long and prostate gland cells are well developed. The ovary is entire and median or submedian in position. The large receptaculum seminis is present behind ovary; a little in front of hinder end. Uterus is much coiled at its posterior half; metraterm is large, saccular, highly muscular

and is armed internally with scattered spines. Eggs are numerous (Photo 41), yellowish brown and operculated (Photo 41) with fine filament at non-operculated end. Vitelline follicles are scattered across the entire posterior body. Excretory vesicle is "Y" or "V" shaped with subterminal pore. They are parasitic in intestine of the crocodiles.

4.3.2.2 Keys to genera of Exotidendriidae:

The genus *Exotidendrium* can be diagnosed considering its two main characters; one is ovary which is basically post-testicular and occasionally intertesticular in position and another is the vitellaria that are present at the posterior part of the body.

PLATE XI

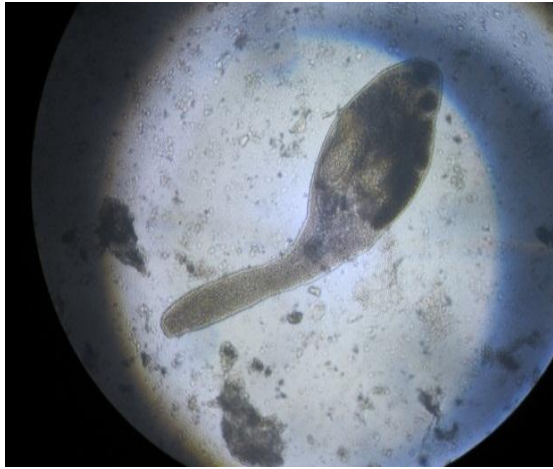

Photo 36(10X x 10X)

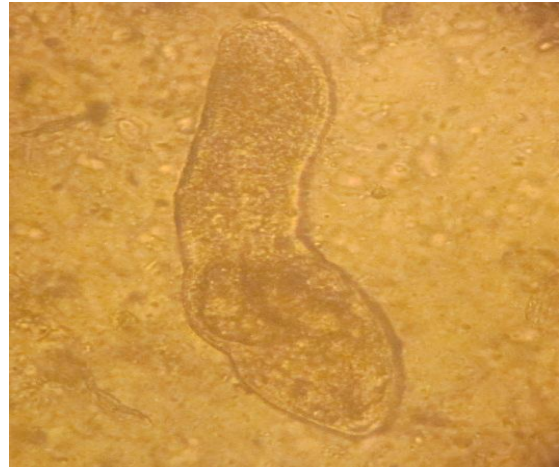


Photo 37(10X x 20X)

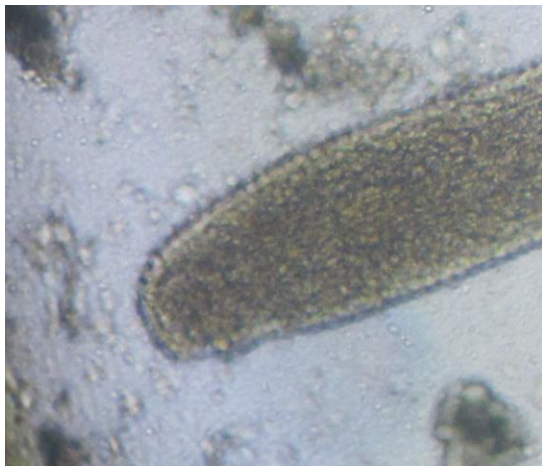

Photo 38(10X x 40X)

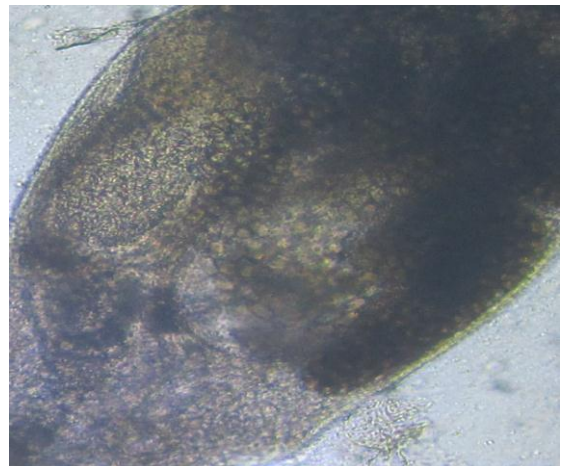


Photo 39(10X x 40X)

Photo 36: Whole body of mature *Exotidendrium* sp. Photo 37: Whole body of immature *Exotidendrium* sp. Photo 38: Anterior slender region with oral sucker. Photo 38: Broad region of body with two testes: just after the ventral sucker.

PLATE XII

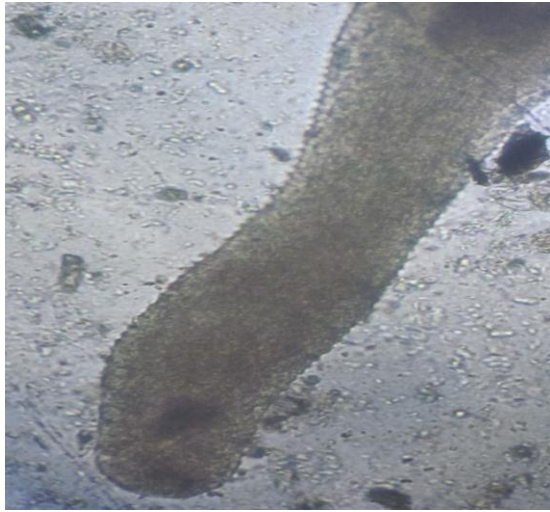

Photo 40(10X x 40X)

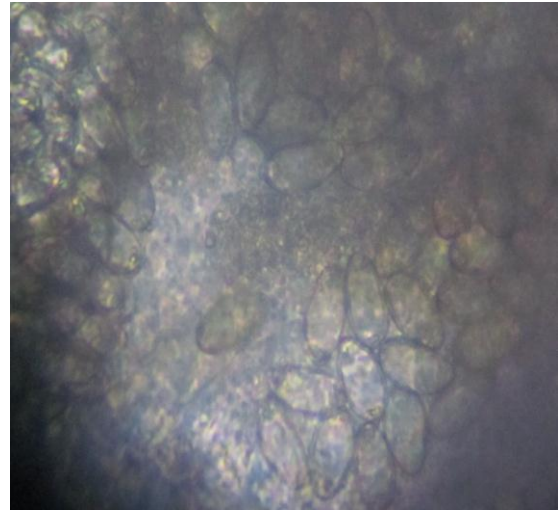


Photo 41(10X x 20X)

Photo 40: Anterior slender region showing the cuticular spines. Photo 41: A portion of trematode body filled with the brownish operculated eggs.

PLATE XIII

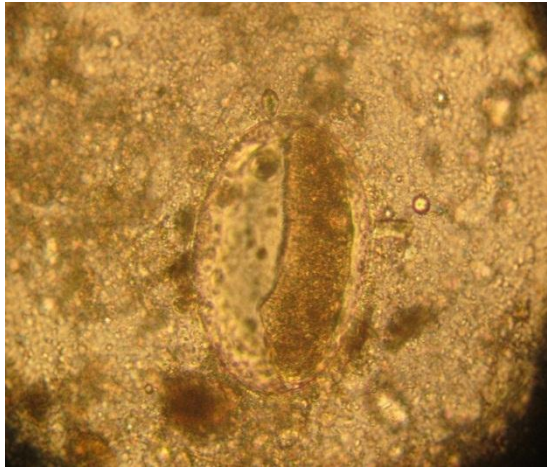


Photo 42(10X x 40X)

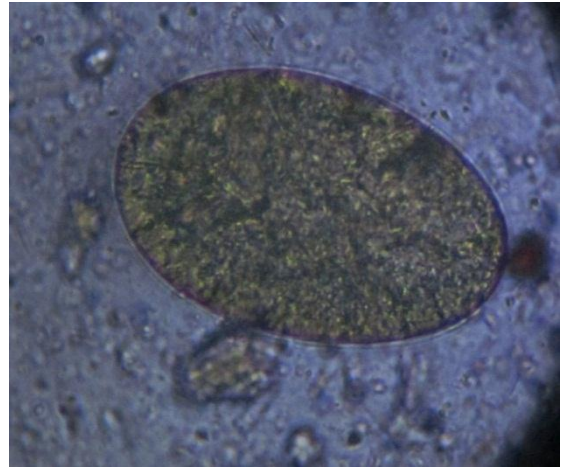


Photo 43(10X x 40X)

Photo 42: An unidentified embryonated egg from intestine. Photo 43: An unidentified operculated egg from intestine.

4.4 Distribution of parasites in gharials:

A total 85 death gharial hatchlings were dissected for the study of gastrointestinal helminth parasites. The study was conducted for six months from July to December of the year 2012. The dead gharials were dissected and various visceral organs were microscopically examined. Out of 85 dead hatchlings examined, the overall prevalence of parasites was found to be 47.06% (fig. 2).

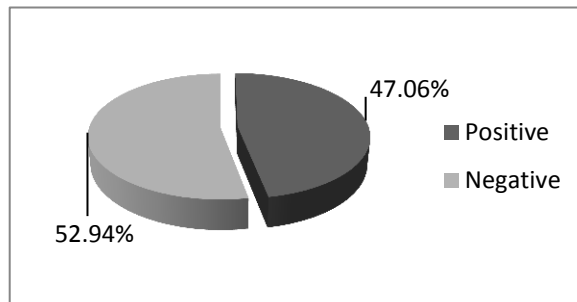


Figure 2: Overall prevalence of gastrointestinal helminth parasites.

Among the gastrointestinal helminth parasites identified Pentastomid (41.17%) showed the highest prevalence followed by *Exotidendrium* sp. (36.47%), Ascaridoids (7.05%), *Proctocaecum gairhei* (3.52%) and Capillarioids (1.17%) in death gharial hatchlings that were hatched at GBC, Chitwan National Park, Nepal (Table 5).

Table 5: General prevalence of gastrointestinal helminth parasites in gharials:

S.N.	Endoparasites	Frequency (percentage) (n=85)
1	Pentastomid	35(41.17%)
2	Nematodes	
	a. Ascaridoids	6(7.05%)
	b. Capillarioids	1(1.17%)
3	Trematodes	
	a. <i>Proctocaecum gairhei</i>	3(3.52%)
	b. <i>Exotidendrium</i> sp.	31(36.47%)

During the study periods from July to Dec, in the month of July *Exotidendrium* sp. (8%) showed highest prevalence; parasites Pentastomid (4%) and Capillarioids (4%) showed equal prevalence rate in the. In August, Pentastomid (40.74%) showed highest prevalence and then *Exotidendrium* sp. (33.33%) and was followed by Ascaridoids (11.11%). Similarly, in September Pentastomid (57.14%) showed highest prevalence then *Exotidendrium* sp. (42.85%) and was followed by Ascaridoid (14.28%). In October, Pentastomid (70%) and *Exotidendrium* sp. (70%) showed equal prevalence rate followed by Ascaridoids (20%). In November and December Pentastomid showed highest prevalence 80% and 100% respectively followed by *Exotidendrium* sp. 60% and 100% respectively (Table 6).

Table 6: Monthwise prevalence of gastrointestinal helminth parasites of gharials:

S.N.	Endoparasites	Months					
		Jul(n=25)	Aug(n=27)	Sept(n=14)	Oct(n=10)	Nov(n=5)	Dec(n=4)
1	Pentastomid	1(4%)	11(40.74%)	8(57.14%)	7(70%)	4(80%)	4(100%)
2	Nematodes						
	a. Ascaridoids	0(0%)	3(11.11%)	2(14.28%)	2(20%)	0(0%)	1(25%)
	b. Capillarioids	1(4%)	0(0%)	0(0%)	0(0%)	0(0%)	0(0%)
3	Trematodes						
	a. <i>Proctocaecum gairhei</i> .	0(0%)	0(0%)	0(0%)	0(0%)	0(0%)	3(75%)
	b. <i>Exotidendrium</i> sp.	2(8%)	9(33.33%)	6(42.85%)	7(70%)	3(60%)	4(100%)

In the first age group from 1-5 weeks showed no any prevalence of gastrointestinal helminth parasites. The age group from 5-9 weeks, *Exotidendrium* sp. (8.33%) showed highest prevalence and Pentastomid (4.16%) and Capillrioids (4.16%) showed equal prevalence rate. In the age group 9-13 weeks, Pentastomid (46.15%) showed highest prevalence followed by *Exotidendrium* sp. (42.30%) and then Ascaridioids (11.53%). Similarly, in the age group 13-17 weeks, Pentastomid (58.33%) showed highest prevalence followed by *Exotidendrium* sp. (33.33%) prevalence and others showed no any positive case. The age group 17-21 weeks have equal prevalence of Pentastomids (70%) and *Exotidendrium* sp. (70%) followed by Ascaridoid (20%). In the age groups 21-25 weeks, Pentastomid (80%) showed highest prevalence rate followed by *Exotidendrium* sp. (60%), while other showed no any positive cases. The age groups 25-29 weeks have equal prevalence of pentastomid (100%) and *Exotidendrium* sp. (100%) followed by *Proctocaecum gairhei* (75%) and then Ascaridioids (25%) (Table 7).

Table 7: Age wise prevalence of gastrointestinal helminth parasites in gharials:

Age groups(Weeks)	Pentastomids	Nematodes		Trematodes	
		Ascaridoids	Capillarioids	<i>Proctocaecum gairhei</i>	<i>Exotidendrium</i> sp.
1–5(n=4)	0(0%)	0(0%)	0(0%)	0(0%)	0(0%)
5–9(n=24)	1(4.16%)	0(0%)	1(4.16%)	0(0%)	2(8.33)
9–13(n=26)	12(46.15%)	3(11.53%)	0(0%)	0(0%)	11(42.30%)
13–17(n=12)	7(58.33%)	0(0%)	0(0%)	0(0%)	4(33.33%)
17–21(n=10)	7(70%)	2(20%)	0(0%)	0(0%)	7(70%)
21–25(n=5)	4(80%)	0(0%)	0(0%)	0(0%)	3(60%)
25–29(n=4)	4(100%)	1(25%)	0(0%)	3(75%)	4(100%)

5. DISCUSSION

The gharial (*Gavialis gangeticus*-meaning-'clay pot with long neck') is exclusively the fresh water reptile which is found in Northern Indian subcontinent in river drainages of India, Pakistan and Nepal. Besides this, it is found in very low number or extinct in Bangladesh, Bhutan and Burma. It is only the living species of the family: Gavialidae. Gharials have elongated and narrow snout; many interlocking, razor like sharp teeth are present in its jaws. They have well developed laterally flattened tail and webbed rear feet for moving in fast flowing water habitat. Their ventral body scales are provided with sensory pits. Male have bulbous growth on the tip of snout while that is absent in female.

The St. Augustine Alligator farm established in 1893 is the early crocodile farm that was established with the main aim of tourist attractions. After 20th century many crocodiles were kept under protection act by the Convention on International Trade in Endangered Species (CITIES) for gaining stocks of endangered species of crocodiles. Later on, after 1960s harvesting of wild eggs was started mainly focusing for the preservation of the nearly extinct ones. The inclusions of many American alligators under official protection acts, farming of alligators shaped one of the options for production of leathers which cost hundreds of dollars for a single piece. Besides this, crocodile's meat is consumed in many countries like Ethiopia, Thailand, Australia, Cuba, South Africa and some parts of the United States. They are also used for the extraction of oils used for various purposes.

Crocodile suffers from various kinds of diseases and defects from its early embryonic to late adult stages. Various kinds of diseases of eggs such as lower degree of porosity of eggs, soft shell, partial shell formation, complete absence of shell, under or oversized eggs, eggs hatched at the moist environment and dislodging of embryo inside egg due to careless handling of banded eggs during collections are the major factors for the early death of embryo at the breeding centers. Besides this crocodile hatchlings and adults are vulnerable to various kinds of viral infections such as caiman pox, crocodile pox, adenoviral infection, Newcastle disease and influenza C virus. Similarly, different kinds of bacterial infections such as salmonellosis, mycoplasmosis, chlamydiosis, mycobacteriosis, erysipelothrix, clostridiosis and dermatophilosis are the major bacterial infections. Some of the fungal infections like fungal dermatitis, respiratory mycosis,

gastrointestinal mycosis, oral mycosis, generalized mycosis and various kinds of protozoal infections and coccidiosis are also responsible for the causing diseases in crocodiles.

Crocodiles at wild and captive forms are affected by various kinds of ecto and endoparasites. The major endoparasites reported in crocodiles are *Giardia* sp., *Leishmania* sp., *Trypanosoma* sp., *Entamoeba* sp., *Blastocystis* sp., *Brevimulticaecum* spp., *Dujardinascaris* spp., *Gedoelstascaris* spp., *Goezia* spp., *Hartwichia* spp., *Multicaecum* spp., *Ortleppascaris* spp., *Terranova* spp., *Typhlophorus* spp., *Crocodylocapillaria longiovata*, *Paratrichosoma* spp., *Trichinella*, *Micropleura* spp., *Oswaldofilaria* spp., *Coenorhabditis* sp., *Polyacanthoryhchus rhopalorhynchus*, *Polymorphus mutabilis* (Cuban crocodiles), *Gnathostoma procyonis* (American alligators), *Acanthostomum* spp., *Odhneriotrema* spp., *Allechinostomum* spp., *Archaeodiplostomum* spp., *Atrophocaecum* spp., *Caimanicola marajoira* (*C. crocodilus* 1993), *Capsulodiplostomum crocodilinum* (*C. palustris* 1966), *Crocodylicola caimanicola* (*C. latirostris* 1935), *Crocodylicola gavialis* (*G. gangeticus*), *Cyatocotyle* spp., *Cystodiplostomum hollyi* (Hughes et al. 1941), *Exotidendrium gharialli* (Hughes et al. 1941), *Haromotrema* spp., *Pseudocrocodylicola* spp., *Pseudoneodiplostomum* spp., *Timonella absita* (Blair et al. 1988) and *Exotidendrium* sp. (Foggin 1992). Similarly, *Hirudinaria manillensis* (buffalo leech), *Philobdella gracilis* (*Viosca* 1962), *Placobdella* spp., *Anophles stephensi*, *Culex dolosus*, *Glossina palpalis*, *Triatoma infestans* and *Amblyomma* spp. are the major ectoparasites. Pentastomids like *Caepholobaena* spp., *Raillietiella* spp., *Sebekia* spp., *Alofia* spp., *Leiperia* spp., *Diesingia* sp., *Selfia* spp., *Agema* spp., *Subtriquetra* spp. and *Sambonia* spp. are the parasites of the of the respiratory tract.

The overall prevalence of gastrointestinal helminth parasites were found to be 47.06% and no such specific overall prevalence of gastrointestinal helminth parasites were calculated in the early studies. According to the present findings pentastomid infections (41.17%) which is greater than prevalence (8.76%) in previous study (Gairhe 2007). Previously, these pentastomids were included in the cestodes, but according to some of the characters (Gairhe 2007) of its cyst, number of larval hooks and some general body measurements we concluded this parasites as pentastomids. In the present study, the details of various characteristics were studied by using various taxonomic keys and hence

the isolated pentastomid is assigned to the genus *Sebekia*. The species level was not identified due to the lack of most of the anatomical information in the present study.

Fish do not harbor adult pentastomes, but they are common intermediate hosts for pentastome species of crocodilians and piscivorous chelonians, and rarely for some pentastomes of snakes (Paré 2008). Species so far known from fish hosts are *Sebekia mississippiensis*, *S. oxycephalum*, *Subtriquetra subtriquetra*, *S. rileyi*, *Leiperia cincinnalis*, *L. gracilis*, *Kiricephalus pattoni*, *Railltiella* sp. and *Alofia* sp. Fish become infected when they ingest infective ova. Primary larvae migrate to viscera, muscles, swim bladder, or other tissues of the infected fish to encyst and develop into nymph. The parasite burden may even kill the fish, especially small species. Fish may also be a source of infection for captive crocodilians (Paré 2008).

The gharials at breeding center at Chitwan National Park are commonly feed with the fishes belonging to the family: Cyprinidae; *Aspidoparia morar* (commonly called Chepua), *Barilius* spp. (commonly called chepua), *Labeo* spp. (commonly called rohu), *Barilius bendelisis* var. *chedra* (commonly called motia), *Hypothalalmichtys* spp. (commonly called silver carp) and *Puntius* spp. (commonly called sidhre) and family: Cichlidae; *Tilapia* spp. (commonly called tilapia). Various larvae and adult pentastomes were reported from various parts of fishes that belong to the family Cichlidae; *Alofia* sp. (larvae in swim bladder) of Mossambique bream "tilápia" (*Oreochromis mossambicus*, Peter 1898), *Leiperia cincinnalis* (experimentally infected with primary larvae); *Leiperia cincinnalis* (nymph in muscle) of fresh water latid fish *Tilapia nilotica* (Linnaeus 1758); *Leiperia cincinnalis* (nymphs in body cavity) of fish *Serranochronis meridianus* (Jubb 1967); *Sebekia oxycephalum* (infective larvae) and *Subtriquetra subtriquetra* (developmental stages) from *Tilapia* (smith 1840), *Sebekia minor* (infective larvae) and *Subtriquetra rileyi* (infective larvae) from *Tilapia rendalli* (Boulenger 1897) and *Sebekia oxycephalum* (nymphs in viscera) from *Tilapia zilli* (Gervais 1848). Similarly, pentastomid from family: Poeciliidae; *Sebekia mississippiensis* and *S. oxycephalum* (infective larvae) from a mosquito fish *Gambusia affinis affinis* (Baird and Girrad 1853) and from family Clupeidae; *Leiperia gracilis* and *Sebekia oxycephalum* (larva) from a marine fish *Clupea tobarana* (Natterer 1836). No such investigations related to pentastomids were carried out in Nepal.

Two new nematodes belonging to the family Ascarididae (7.05%) and family Capillaridae (1.17%) has been reported in the present study. An adult fileroid nematode belonging to the family Micropleurinae was reported (Gairhe 2007) from the abdominal cavity of only one death gharial hatchlings with prevalence of 0.73% but no fileroid nematode has been reported in this study. Only the characteristics of the family Ascarididae was described due to the loss of major portion of the adult nematode and was too confirmed by the detection of the characteristics *Ascaris* eggs in the intestine of the same gharial hatchling and few others. Besides this, various types of ascaridoid species were reported from different crocodilians host indicating its rich biodiversity. Ascaridoids such as *Dujardinascaris woodlandi* (Sprent 1977), *Goezia gavialidis* (Sprent 1978), *Multicaecum agile* (Sprent 1979) and *Typhlophorus lamellaris* (Sprent 1983) are the major nematodes reported from the host *Gavialis gangeticus*. The life cycle of *Dujardinascaris* may involves an encysted stage in fish. When the encysted fish were swallowed by the crocodile, the third stage larvae emerge in the stomach and then develops to fourth stage and finally to an adult stage. Adult stage of *D. gedoelsti* and *D. dujardini* were reported from young crocodiles farmed at Zimbabwe (Foggin 1987). So, in the present study the infection may be from infected fish used to feed.

Various types of capillarioids were reported from different crocodilians. In the present study, characteristic egg with elongated polar ends of capillarioids have been reported from intestine of only one dead hatchling with the prevalence of (1.17%). No such reports related to capillarioids were found in Nepal for comparative studies. *Crocodilocapillaria longiovata* (Ladds et al. 1990) is the only one capillarioid that has been reported from gastric glands of stomach of the *Crocodylus porosus*, *C. johnsoni* and *C. novaeguinaea*. However, this parasites shows no any tissue reactions. Similarly, capillarioid *Paratrichosoma* spp. (Solger et al. 1877) from the ventral skins of *C. acutus*, *C. moreletii* and *C. novaeguinaea*. These parasites cause zig-zagging cutaneous trail on ventral skin and larvae are released to the water which may be engested by another crocodilians host. However, this species has also no significant effects of the skin of crocodiles.

Proctocaecum gairhei has been reported (Gairhe 2007) in death gharial hatchlings from same study area in Chitwan National Parks with prevalence rate of 5.84% which is greater than the present prevalence rate (3.52%) in the present study. The trematode of this species is responsible for enlargement and shortening of the duodenum and the gross thickening of the mucosa at the opening of the bile duct into the duodenum and was

observed in the two dead hatchlings (Gairhe 2007). So, the hatchlings may suffer from stress and this may effects the normal physiology of digestion.

Similarly, *Exotidendrium* sp. has also been reported in this present study with the prevalence of 36.47% which is nearly equal to the average prevalence (40.95%) including the immature and mature stages (Gairhe 2007) of this trematode. The parasites is responsible for the pathological condition called "Sphincter cap" (Gairhe 2007) which is characterized by a distinct whitish, blackish, yellowish and yellowish green or greenish granulomatous scab formed around the colorectal orifice of the gharial hatchlings. The prevalence of distinct sphincter cap was found to be 26.60% (Gairhe 2007). However, no such lesions were noted in the present study. A highly significant correlation between distinct sphincter cap and prevalence rates was calculated in the previous study. Similarly, the two trematode species was unidentified due to the lack of available literature related to the *Gavialis gangeticus*.

6. CONCLUSIONS AND RECOMMENDATIONS

A total of 85 dead gharial hatchlings were examined for the presence of gastrointestinal helminth parasites for the duration of six months of gharial hatchlings batch 2012. During this study the overall prevalence of gastrointestinal helminth parasites was found to be 47.06%. Among the gastrointestinal helminth parasites identified the pentastomid *Sebekia* (41.17%) showed the highest prevalence followed by trematode, *Exotidendrium* sp. (36.47%), nematode, Ascaridoid (7.05%), *Proctocaecum gairhei* (3.52%) and then Capillarioids (1.17%). The study showed high prevalence of helminthic infections in dead gharial hatchlings in gharial breeding Centre, Kasara of Chitwan National Park. The specific identifications of nematodes were not possible because major portion of the adult nematodes were lost during the exposure of the intestine. The high prevalence of gastrointestinal helminth infections could be due to that they are not fed with any kinds of anthelmintic except some vitamins. Besides this, the hatchlings are fed with raw fish which are not under proper cold treatment which can be one of the major sources of helminth infections.

During the study high prevalence of pentastomid infections was observed. This is the first report of pentastomids from Nepal. The two species of pentastomid *Alofia indica* (adults in lungs and trachea); *Subtriquetra megacephalum*; *Subtriquetra Shipley* (in pharynx) were reported in *Gavialis gangeticus* (Gmelin 1789) from India. The presently reported all larval pentastomid *Sebekia* sp. was reported from mesenteries of dead gharial hatchlings. One of the major source for the pentastomid infections is the fish. Generally, the fish do not harbor the adult pentastomes, but they act as common intermediate hosts of many pentastomid species of crocodilians, piscivorous chelonians and rarely some snakes (Paré 2008).

Besides this, the presence of *Proctocaecum gairhei* can also be one of the co-factor for the gharial mortality, although there is no such literature associated with the mortality of crocodile hatchlings. But this trematode is associated with the enlargement and shortening of the duodenum and the gross thickening of the mucosa at the opening of the bile into duodenum (Gairhe 2007). Such conditions may hamper the normal physiology of digestion and can weaken the resistant power of young gharial hatchlings.

Similarly, presence of *Exotidendrium* sp. is also the another factor that is responsible for the production of another lesions "Sphincter Cap" characterized by distinct whitish, blackish, yellowish, yellowish-green or greenish granulomatous scab formed around the colorectal orifice of the hatchlings; presence of large number of bacteria were also reported (Gairhe 2007). So, the presence of such kinds of harmful helminths suggests and points for the improvements towards management practices of gharial breeding center with proper medication and treatments. Some of the common recommendations that should be adopted in the farm in order to reduce the gharial mortality rate are:

- ❖ Locally collected fishes that are obtained from polluted Rapti river are infected with number of parasites so before fed to gharials should be frozen for 72 hours to kill the parasitic larvae present inside the fishes (Foggin 1922).
- ❖ Proper anthelmintic should be provided to reduce the helminthic infections.
- ❖ Fishes obtained from suitable source and fishes with suitable size should be fed to the gharial hatchlings.
- ❖ The microbial quality of water in the pool should be regularly checked and sterilization of water should be done as required.
- ❖ Proper sanitation should be maintained and equipment required for proper sanitation should be provided to the care takers.
- ❖ A proper and well equipped laboratory should be established in the breeding farm so one can easily study the different disorders and abnormalities present in gharial hatchlings.
- ❖ The death hatchlings should be removed immediately from the water and no further contamination takes place and gathering of ants other insects are avoided.

7. REFERENCES

- Adams, L., Isaza, R. and Greiner, E. 2001. Fatal pentastomiasis in captive African dwarf crocodile hatchlings (*Osteolaemus tetraspis*). *Journal of zoo and wildlife medicine* **32**(4): 500-502.
- Bhatta, R. 2009. Study on status, distribution and threats to gharial in Rapti river of Chitwan National Park, Nepal. A report submitted to British Ecological Society (BES), U.K.
- Blair, D., Brooks, D.R., Puridie, J. and Melville, L. 1988. *Timoniella absita* n. sp. (Digenea: Cryptogonimidae) from salt water crocodile (*Crocodylus porosus* Schneider) from Australia. *Canadian journal of zoology* **66**: 1763-1766.
- Blair, D., Puridie, J. and Melville, L. 1989. *Renivermis crocodylii* (Digenea: Exotidendriidae) n. g., n. sp. from the kidney of the salt water crocodile *Crocodylus porosus* in Australia. *Systematic parasitology* **14**(3): 181-186.
- Brochu, C.A. 2000. Phylogenetic relationship and divergence timing of *Crocodylus* based on morphology and fossil records. *Copeia* **200**(3): 657-673.
- Christoffersen, M.L. and De Assis, J.E. 2013. A systematic monograph of the Recent Pentastomida, with a compilation of their hosts. *Zoologische Mededelingen Leiden* **87**(1): 29.
- Dhital, R.R. and Jha, D.K. 2001. Fish fauna of the Narayani River system and their impact on the fisherman community in Chitwan Nepal, Department of Fisheries and Aquaculture, IAAS, Rampur Campus, Chitwan, Nepal.
- Enabulele, E.E., Ozemoka, H.J., Asharitoma, A.O. and Aisien, M.S.O. 2013. Parasitic infections of the African dwarf crocodile (*Osteolaemus tetraspis*) and the ornate Nile monitor (*Varanus ornatus*) from Nigeria. *Acta Parasitologica* **58**(2): 191-197.
- Gairhe, K.P. 2007. An investigation on the cause of mortality in captive gharial hatchlings at the Chitwan National Park, Nepal. M.V.Sc. Thesis. Institute of Agriculture and Animal Science, Tribhuvan University, Rampur, Nepal.
- Huchzermeyer, F.W. 2002. Disease of farmed crocodiles and ostriches. *Revue scientifique et technique-office international des epizooties* **21**(2): 265-276.

- Huchzermeyer, F.W. 2003. Crocodiles: Biology, husbandry and diseases. Wallingford, CABI Publishing. p. 167-170.
- Huchzermeyer, F.W. and Riley J. 1995. Pentastomid parasites of the family Sebekidae Fain, 1961 in West Africa dwarf crocodiles *Osteolaemus tetraspis* Cope, 1851 from the Congo, with a description of *Alofia parva* n. sp. Onderstepoort Journal of Veterinary Research **62**: 151-162.
- Junker, K. and Boomker, J. 2006. A check-list of the Pentastomid parasites of crocodylians and freshwater chelonians. Onderstepoort Journal of Veterinary Research **73**: 27-36.
- Junker, K., Boomker, J., Swanepoel, D. and Taraschewski, H. 2000. *Leiperia cincinnalis* Sambon, 1999 (Pentastomid) from Nile crocodiles *Crocodylus niloticus* in the Kruger National Park, South Africa, with the description of the male. Systematic Parasitology **47**: 29-41.
- Junker, K., Brooks, R.D. and Boomker, J. 2008. *Proctacaecum gairhei* n. sp. (Digenea: Cryptogonimidae: Acanthostomidae) from *Gavialis gangeticus* (Gmelin) in Nepal and a revised cladogram of *Proctacaecum* Baugh, 1957. Systematic parasitology **71**: 229-236.
- Junker, K., Riley, J. and Boomker, J. 2003. Redescription of *Diesingia megstoma* (Diesing, 1836) Sambon, 1922, a pentastomid parasite from the South American terrapin *Hydromedusa tectifera* Cope. Systematic Parasitology **56**: 211-218.
- Junker, K., Wallace, K., Leslie, A.J. and Boomker, J. 2006. Gastric nematodes of Nile crocodiles, *Crocodylus niloticus* Laurenti, 1768, in the Okavango River, Botswana. Onderstepoort Journal of Veterinary Research **73**: 111-114.
- Linstow, V. 1906. Parasites from the gharial (*Gavialis gangeticus*, Geoffr.). Journal of Asiatic Society of Bengal **2**(7): 269-271.
- Mehra, H.R. 1935. New trematodes of the family Lecithodendriidae Odhner, 1911 with a review of the classification of the family. Proceedings of the academy of sciences (United provinces of the Africa and Oudh, India) **5**(1): 99-121.
- Moravec, F. 2001. Some helminth parasites from Morelet's crocodile, *Crocodylus moreletii*, from Yucatan, Mexico. Folia parasitologica **48**: 47-62.
- Moravec, F. and Garibaldi, F. 2000. *Huffmanella paroni* sp. n. (Nematoda: Trichosomoididae), a new parasite from the skin of swordfish *Xiphias gladius* in the Ligurian sea (Western Mediterranean). Folia Parasitologica **47**: 309-313.

- Moravec, F., Kay, W.R. and Hobbs, R.P. 2004. *Micropleura australiensis* n. sp. (Nematoda: Micropleruidae) from the body cavity of *Crocodylus johnsoni* in Western Australia. *Journal of parasitology* **90**(2): 322-326.
- Narain, D. 1930. *Neodiplostomum gavialis* n. sp. from the crocodile. *Journal of parasitology* **16**: 154-157.
- Overstreet, R.M., Self, T. and Vliet, K.A. 1985. The Pentastomid *Sebekia mississippiensis* sp. n. in the American Alligator and Other Hosts. *Proceedings of the Helminthological Society* **52**(2): 266-267.
- Riley, J., Hill, G.F. and Huchzermeyer, F.W. 1997. A description of *Agema*, a new monotypic pentastomid genus from the lungs of the African dwarf and slender snouted crocodiles. *Systematic Parasitology* **37**: 207-217.
- Riley, J. and Huchzermeyer, F.W. 1995. Description of four species of Pentastomid parasite belonging to the genera *Alofia* Giglioli, 1922 and *Sebekia* Sambon, 1922, from a single Nile crocodile *Crocodylus niloticus* from Botswana. *Systematic parasitology* **31**: 221-238.
- Riley, J. and Huchzermeyer, F.W. 2000. Diet and lung parasite of swamp forest dwarf crocodiles (*Osteolaemus tetraspis osborni*) in Northern Congo Republic. *Copeia* **2**: 582-586.
- Rossin, M.A. and Timi J. T. 2009. A new species of Paracapillaroides (Nematoda: Capillariidae) parasitizing *Nemadactylus bergi* (Perciformes: Latridae) from the Argentine Sea. *Folia Parasitologica* **56**(1): 37-40.
- Sharma, C. M. 2008. Freshwater Fishes, Fisheries, and Habitat Prospects of Nepal. *Aquatic Ecosystem Health and Management* **11**(3).
- Shrivastava, C.B. 1981. Intraspecific variations in *Exotidendrium gharialii* Mehara, 1935 with a review of the family Exotidendriidae Mehara, 1935 status emended Srivastava, 1977 (Trematoda: Digenea). *Journal of zoological society of India* **33**(1 and 2): 131-139.
- Sprent, J.F.A., Mckeown, E.A. and Cremin, M. 1998. *Dujardinascaris* spp. (Nematoda: Ascaridoidea) in Old World crocodilians. *Systematic Parasitology* **39**: 209-222.
- Tellez, M. and Darand, J.P. 2011. Nematoda infection of the ventral scales of the American crocodile (*Crocodylus acutus*) and Morelet's crocodile (*Crocodylus moreletii*) in Southern Belize. *Comparitive parasitology* **78**(2): 378-381.

- Tkatch, V.V. and Synder, S.D. 2010. *Proctocaecum blairi* sp. nov. (Digenea, Cryptogonimidae) from the freshwater crocodile, *Crocodylus johnstoni* in Northern Territory, Australia. *Acta Parasitologica* **55**(3): 240-244.
- Tubnagui, M.A. and Masilungan, V.A. 1936. Trematode parasites of phillippine vertebrate, VII. Flukes from a cobra and a crocodile. *The phillipine journal of science* **60**: 255-260.
- Villegas, A. and González-Solis, D. 2009. Gastrointestinal helminth parasites of the American crocodile (*Crocodylus acutus*) in Southern Quintana Roo. *Mexico herpetological conservation and biology* **4**(3): 346-351.
- Waddle, A.R., Kinsella, J.M., Ross, J.P. and Forrester, D.J. 2009. Nematodes collected by gastric lavage from live American alligators, *Alligator mississippiensis* in Florida. *Journal of parasitology* **95**(5): 1237-1238.
- Waloszek, D., Repetski, J.E. and Mass, A. 2006. A new Late Cambrian Pentastomid and a review of the relationship of this parasitic group. *Transactions of the Royal Society of Edinburgh: Earth Sciences* **96**: 163-17.